10.5005/jp-journals-10024-1334
ORIGINAL RESEARCH

A Double Blind Study on the Efficacy of Local Application of Hemocoagulase Solution in Wound Healing

Sachin Aslam, PG Francis, BHS Rao, M Ummar, JK Issac, RB Nair

ABSTRACT

Aim: The present double blind study has been designed to evaluate the efficacy of local application of hemocoagulase solution as compared to a placebo in wound healing following dental extraction.

Materials and methods: A total of 20 patients who required dental extraction for orthodontic intervention were included. The hemocoagulase solution and a placebo were locally applied to the extraction sockets and the efficacy of the solution in terms of bleeding control, anti-inflammatory responses, its antiseptic properties and efficacy in wound healing were evaluated.

Results: The mean time required to achieve hemostasis was found to be 1.37 minutes in side A (test) and 2.33 minutes in side B (control) indicating that side A achieved faster hemostasis when compared to side B. At the 6th hour postoperatively, bleeding was not evident on either sides, and the amount of pain in side A was found to be less compared to side B. The number of RBCs, polymorphs, chronic inflammatory cells were not different in both the groups, whereas at 3rd postoperative day epithelial cells were greater in side A (test) compared to side B (control). Biopsy reports on the 12th postoperative day indicated that the number of fibroblasts, epithelial cells, collagen count was found to be greater in side A (test) compared to side B (control).

Conclusion: The topical hemocoagulase solution may be advocated in the field of oral and maxillofacial surgery, as a hemostatic agent and promoter of wound healing. However, further studies, with large number of cases and different clinical situations should be considered to authenticate the efficacy of this hemocoagulase solution in the practice of oral and maxillofacial surgery.

Clinical significance: Wound healing plays an important role in the success of any surgical procedure, such as extractions, and the hemocoagulase system may act as a hemostatic agent and a promoter of wound healing.

Keywords: Hemocoagulase, Case-control, Surgery, Hemostasis, Wound healing.

How to cite this article: Aslam S, Francis PG, Rao BHS, Ummar M, Issac JK, Nair RB. A Double Blind Study on the Efficacy of Local Application of Hemocoagulase Solution in Wound Healing. J Contemp Dent Pract 2013;14(3):394-400.

Source of support: Nil

Conflict of interest: None declared

INTRODUCTION

In the practice of oral and maxillofacial surgery a number of clinical situations are encountered where capillary oozing can be an annoying problem. Capillary bleeding can occur during minor procedures such as dental extraction due to major procedures such as reconstruction of deformed or damaged parts of the body and replacement of body parts.

Capillary bleeding implies breakdown in supply of nutrients and oxygen in the area, leading to impaired wound healing. Restoring the capillary tree ensures faster wound healing and hence, reduced inflammation and infection. Control of capillary bleeding leads to decreased morbidity of the patient as it improves healing leading to faster recovery. Thus blood coagulation, inflammation and tissue repair are intricately linked.[1] The healing of wounds is the most interesting of the many phenomena which characterize the living organism. The ability of damaged tissue to repair itself is a response of life itself. Thus, it should be clearly understood that the healing of a wound is not an isolated solitary phenomenon but actually a very complex series of biologic events.[2] Healing of all tissues after injury has an essentially identical pattern, but this healing may be modified considerably depending upon numerous extrinsic and intrinsic factors.

A thorough understanding of the phenomenon of healing of extraction wounds is imperative, since vast numbers of teeth are extracted and there is an ever present possibility of complication in the healing process. Bleeding is one among the factors that impedes healing. So knowledge of the fundamentals of normal and deranged hemostasis is critical for successful and uneventful conduction of a surgical procedure.

Constant research is under process to understand the biologic events and sequence of dynamic events behind healing and to enhance the healing phase. The

hemocoagulase topical solutions are compounds that are applied locally to control surface bleeding and capillary oozing.[3,4] In the past, various modalities have been reported to achieve local hemostasis using agents like microfibrillar collagen, gelatin sponge, topical thrombin, feracrylum, fibrin sealants, etc.[5] These however, tend to cause infection and delay the wound healing. Also they are deficient in achieving efficient local hemostasis.

The hemocoagulase topical solution is an enzyme complex based fundamentally on coagulative and antihemorrhagic properties of those fractions isolated from the poison of '*Bothrops jararaca* or *Bothrops atrox*'. It acts by accelerating the conversion of fibrinogen to fibrin polymer and promotes the interaction of platelets with fibrin clot to coagulate the blood.[1,6] The fibrin clot thus formed is highly resistant to plasmin and encourages the growth of collagen fibers beneath it.[7] Thus, it reduces the bleeding time,[8] enhances cell division and capillary network formation in wound space and hastens wound healing concomitantly arresting capillary bleeding. Being a topical form it also acts fast and is atoxic.

Considering all these therapeutic uses, a double blind study on the efficacy of local application of hemocoagulase solution as compared to a placebo in wound healing following dental extraction was carried out to clinically evaluate its usefulness in the practice of oral and maxillofacial surgery.

MATERIALS AND METHODS

A total of 20 patients from the outpatient Department of Oral and Maxillofacial Surgery, Yenepoya Dental College and Hospital, Deralakatte who required dental extraction for orthodontic intervention were included. The hemocoagulase solution and a placebo were locally applied to the extraction sockets wherein dental extractions were done under local anesthesia bilaterally. The efficacy of the solution in terms of bleeding control, anti-inflammatory responses, its antiseptic properties and in wound healing were the other objectives of the study.

The study protocol was approved by ethical committee of Yenepoya University of Medical Sciences, Deralakatte, Mangalore. After approval the study protocol was explained to the patients and informed consent was obtained. Healthy patients in the 2nd and 3rd decades of life, tooth to be extracted and the neighboring teeth free of infection were included in the study.

PROCEDURE

In all the patients, routine blood investigations were carried out to determine the baseline value of bleeding time, clotting time and hemoglobin. The procedure was performed under local anesthesia (2% lignocaine Hl with adrenaline 1:80,000).

The mucoperiosteum was reflected to expose the bone and tooth, and extraction was performed using the appropriate dental extraction forceps. Following extraction, 1cc of solution A and B were deposited into the sockets respectively (Fig. 1). Both the patients and the surgeon were blinded to the type of solution being placed. A stopwatch was used to record the time from placement of solution up to complete formation of clot (Fig. 2). After placement of solution, the extraction sockets were packed with gauze packs.

Postoperative Care

All the patients were instructed to avoid rinsing for next 24 hours, maintain oral hygiene, adequate rest and mild analgesics were prescribed as required.

Patients were asked to inform in case of bleeding, pain or discomfort. After 6 hours, the patients were asked to

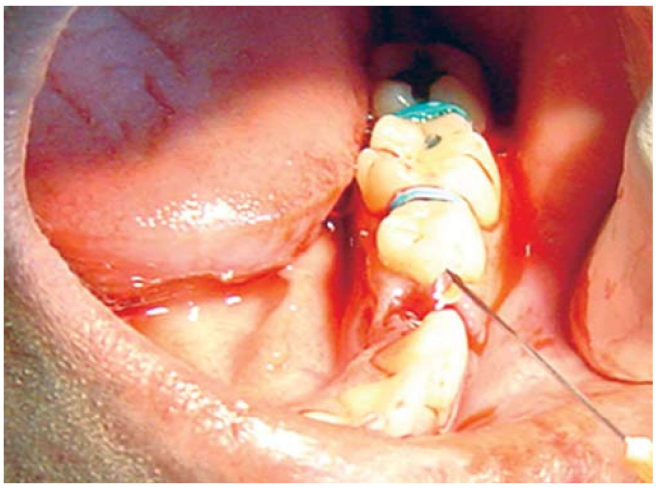

Fig. 1: Deposition of the solution after extraction

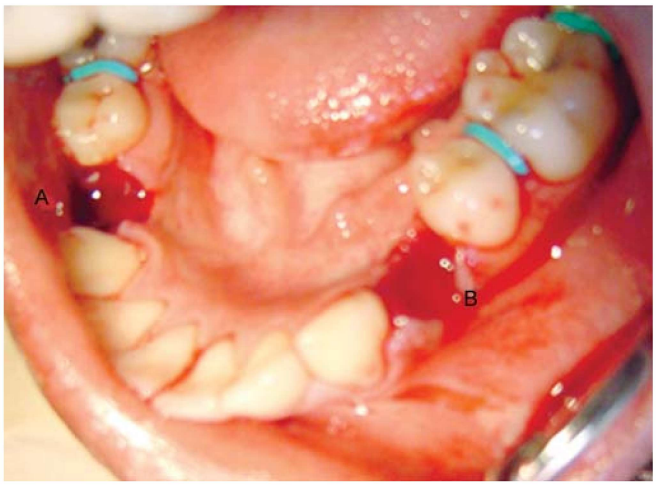

Fig. 2: Formation of clot in both sides A and B

report for clinical examination of the extraction socket for pain and bleeding. A smear was taken from the extraction socket using a sterile swab immediately after extraction and on the third day, and sent for histological examination (Fig. 3). A total of 10 ml of fluid was also taken from the extraction socket and sent for microbiological examination (Fig. 4).

On the 3rd day of follow-up patients were re-evaluated for presence of pain. Out of the 20 patients, five patients were randomly selected and a biopsy was taken for histological examination on the 12th day postoperatively.

RESULTS

Clinical Observations

The time required to achieve hemostasis, immediately, after the application of the solution in side A and B, were found to be within 1.00 to 1.50 minutes and 2.00 to 2.50 minutes, respectively and comparison between the two sides was found to be significant (Table 1).

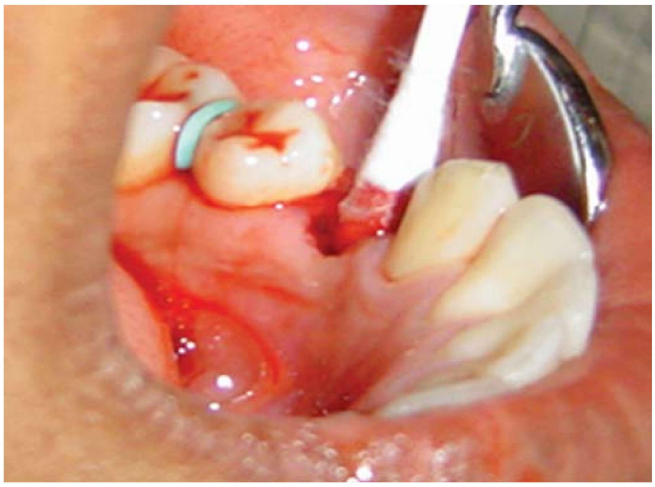

Fig. 3: Smear taken at 6 hours

Fig. 4: Fluid taken at 6 hours

Table 1: Distribution of the patients according to the time required to stop bleeding

		Side		Total
		A	B	
<1	Count	2	0	2
	%	10%	0%	5%
1-1.5	Count	11	0	11
	%	55%	0%	27.5%
1.5-2	Count	5	0	5
	%	25%	0%	12.5%
2-2.5	Count	2	10	12
	%	10%	50%	30%
2.5-3	Count	0	9	9
	%	0%	45%	22.5%
>3	Count	0	1	1
	%	0%	5%	2.5%
Total	Count	20	20	40
	%	100%	100%	100%

$\chi^2 = 32.6$; p = 0.001 (HS); HS: Highly significant

The mean time required to achieve hemostasis in patients who underwent extractions, were then calculated as 1.37 minutes in side A and 2.33 minutes in side B indicating that side A achieved faster hemostasis when compared to side B (Table 2).

Bleeding was not evident at the 6th hour postoperatively on either side. Thus, statistically no significant difference was observed (Table 3).

On comparing both sides for pain at the 6th hour postoperatively, the amount of pain in side A was found to be less compared to side B, and the result was statistically significant (Table 4). There was no pain on the 3rd postoperative day on either sides, and result was found to be statistically insignificant.

Table 2: Distribution of the patients according to the mean time required to stop bleeding

Side	N	Mean	Std. deviation	Total
A	20	1.3735	0.5218	4.2860
B	20	2.3275	0.8480	p = 0.001 VHS

VHS: Very highly significant

Table 3: Distribution of the patients according to bleeding at 6 hours

		Side		Total
		A	B	
No bleeding	Count	20	20	40
	%	100.0%	100.0%	100.0%
Total	Count	20	20	40
	%	100.0%	100.0%	100.0%

Table 4: Distribution of the patients according to pain at 6 hours

		Side		Total
		A	B	
No pain	Count	16	9	25
	%	80.0%	45.0%	62.5%
Mild	Count	4	11	15
	%	20.0%	55.0%	37.5%
Total	Count	20	20	40
	%	100.0%	100.0%	100.0%

$\chi^2 = 5.227$; p = 0.022 (S); S: Significant

Microbiological Observations

Based on the quantification of microbial colonies formed at the 6th hour, postoperative period, it was noted that the mean value in the number of colonies formed in side A and B ranged from 18,500 to 22,500, and the result was statistically insignificant (Table 5).

Histological Observations (Based on Smear Examination)

The RBC count at the 6th hour postoperatively is shown in Table 6, and the result was found to be highly significant (Table 6). On the 3rd day postoperatively, it was found that the amount of RBC's was absent on both sides and the result was insignificant.

The polymorphs at the 6th hour postoperatively, showed that in side A, 19 patients had two plus count and one had one plus count whereas, in side B all the 20 patients had two plus count. Thus, found to be statistically insignificant. The 3rd postoperative day revealed that in side A, two patients had two plus count, six had one plus count and 12 had no count. And in side B, one patient had two plus count, 13 had one plus and in the remaining six patients polymorph's were absent. Thus, statistically no significant changes were noted.

On comparing both sides based on the number of epithelial cells at the 6th hour postoperatively, we found that the epithelial cells were absent on both the sides and result was not significant. The 3rd postoperative day revealed that, in side A, 19 patients had two plus count and one had one plus count. And in side B, 20 patients had one plus count and the result was very highly significant indicating that an increase in number of epithelial cells was found in side A.

The number of chronic inflammatory cells at the 6th hour postoperatively, showed that in side A, four patients had one plus count and the remaining 16 had no chronic inflammatory cells whereas, in side B 16 patients had one plus count and four had no chronic inflammatory cells. Thus, statistically no significant changes were observed. The 3rd day postoperatively, it was found that there was two plus count in seven patients and 13 had one plus count in side A whereas, in side B 14 patients had two plus count and six had one plus count. Thus found to be statistically insignificant.

Table 5: Distribution of the patients according to quantification of total number of colonies

Side	N	Mean	Std. deviation	Z
A	20	18.5000	10.4856	1.7750
B	20	22.2500	7.7655	p = 0.76 NS

NS: Non Significant

Table 6: Distribution of the patients according to the amount of RBC at 6 hours

		Side		Total
		A	B	
+	Count	17		17
	%	85.0%		42.5%
++	Count	2	9	11
	%	10.0%	45.0%	27.5%
+++	Count	1	11	12
	%	5.0%	55.0%	30.0%
Total	Count	20	20	40
	%	100.0%	100.0%	100.0%

$\chi^2 = 29.788$; p = 0.001 (S); Significant

Table 7: Distribution of the patients according to the vascularity on 12th day

		Side		Total
		A	B	
+	Count	5	2	10
	%	100.0%	100.0%	100.0%
Total	Count	5	5	10
	%	100.0%	100.0%	100.0%

Histological Observations (Based on Biopsy Reports of 5 Cases Randomly Selected)

On comparing both sides, fibroblast count on the 12th day postoperatively in side A was to be two plus in three patients and one plus count in two patients. In side B one plus count was present in all the five patients. Thus, significant change with more number of fibroblasts was observed in side A (Fig. 5).

The 12th postoperative day the collagen count in side A was two plus in 3 and 2 one plus in two patients, in side B all the five patients had one plus count. Thus, statistically a significant change with more collagen was observed in side A (Fig. 5).

On the 12th postoperative day, all the five patients had one plus count of chronic inflammatory cells on both sides. Thus, statistically found to be insignificant.

Based on epithelialization on the 12th day postoperatively, on comparing both sides two plus count was found in three

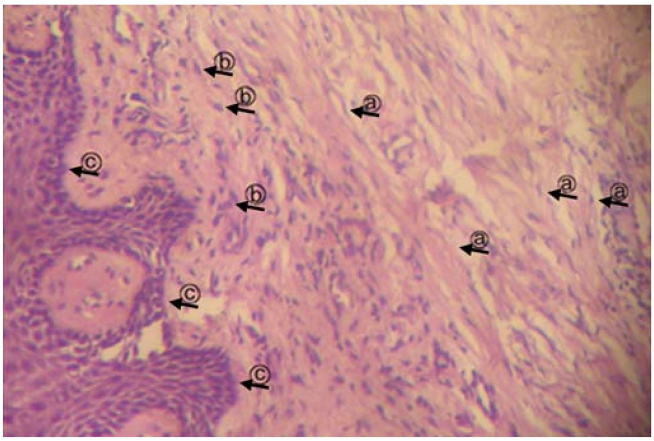

Fig. 5: Histologic section showing more collagen bundles in side A (H&E stain, 40× magnification)

patients and one plus count in two patients in side A, whereas, in side B one plus count was present in all the five patients. Thus, statistically a significant change with more epithelialization was observed in side A (Fig. 6).

On the 12th day postoperatively when vascularity was evaluated, both sides showed one plus count for all the five patients (Table 7). There were no significant changes statistically.

DISCUSSION

Blood coagulation, inflammation and tissue repair are intricately linked.[1] A biostable union between the broken tissue planes is necessary for optimum healing to occur. It is believed that clotting factors generate reparative changes. Fibrin deposition and fibrinolysis are linked to the healing process. Further fibrin degradation products induce angiogenesis and produce a wide variety of biological actions.

Bleeding in oral surgery can be due to a variety of local and systemic factors. Other predisposing factors include, negligence following postextraction instructions. In the past, several of these problems with bleeding required the use of various local hemostatic measures. Pressure packing, suturing the socket, adrenaline pack or acrylic splint of various constructions was being used. However, at times bleeding is largely from capillaries which cannot be controlled by mechanical means, wherein drugs would be of great value. Biological agents such as thrombin, fibrin glue[3] are technically difficult to apply, especially in wet regions such as bleeding extraction sites. They also carry the risk of viral disease transmission, and these agents are very expensive. Postsurgical bleeding in oral surgery is also a well known complication. In some cases, simple compression at the site of bleeding will suffice in obtaining hemostasis,[9] whereas in other cases it calls for more time consuming procedures.

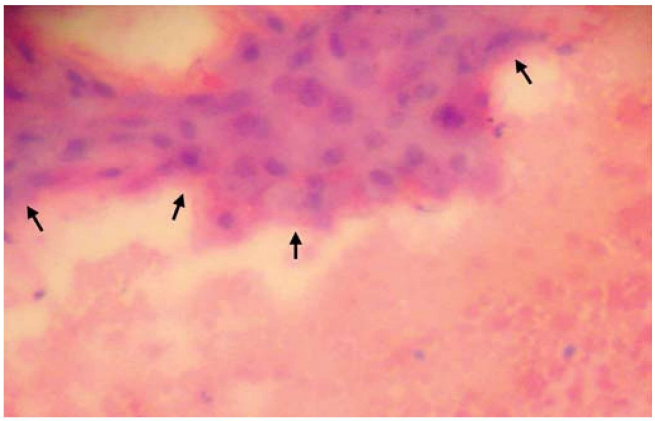

Fig. 6: Photomicrograph showing more epithelial cells in side A (H&E stain, 40× magnification)

Various newer local hemostatic agents have been suggested to be applied locally, on extraction sites, which include tranexamic acid mouthwash, fibrin glue, cyanocrylate, thrombin, microfibrillar collagen and oxidized cellulose.[10]

The actions of the hemocoagulase solution used in the current study, continue even in the presence of antithrombin and are not absorbed in fibrin clot, hence the action is prolonged. Its procoagulant effect and other enzymatic actions have also suggested its role in augmentation of healing. Results have also shown that it increased the wound breaking strength, total collagen content, rate of wound contraction and accelerated epithelialization significantly suggesting that, it is a promoter of wound healing.[1]

In the current study, the solution (A) contained the sterile topical hemocoagulase solution and solution (B) contained sterile water. The comparison between side A and B was done clinically, to determine the mean value for bleeding and it was found that side A had the advantage to achieve faster hemostasis.

The hemostatic properties of the hemocoagulase have been reported previously.[11,12] The effect of the hemocoagulase in reducing the clotting time has been observed previously, where a clotting time of less than 2 minutes was observed in 44% of the patients.[13] Similar findings have been found in the present study suggesting that the hemocoagulase solution is an effective topical hemostatic agent. In addition, it has been reported that exogenous inhibitors of blood coagulation may exhibit distinctive mechanisms of action. Bothrojaracin, a prothrombin ligand from snake-venom *Bothrops jararaca* is one such inhibitor. Since, these proteins target both the active enzymes and their respective zymogens, they display more than one mechanism to impair blood coagulation.[14]

Evaluation of pain based on verbal analog scale showed that, at the 6th hour on side A, there was less pain when

compared to side B and on the 3rd day there was no pain on both the sides. Since, both the extraction sites were free from infection preoperatively; reduction in pain on A side strengthens the fact that this hemocoagulase solution has moderate analgesic action, locally. The analgesic effect has been reported in eight cases of herpes zoster ophthalmoplegia, following use of hemocoagulase.[15] The results obtained by Ramesh et al[7] (1990) also confirmed the effectiveness of hemocoagulase in producing moderate analgesic effect locally.

In view of its antiseptic properties we compared both the sides based on the total number of colonies of microorganisms formed through microbiological examination. Results did not show any significant changes as the sites taken up for the study were free of infection. The antiseptic property of this solution could not be proven in our study and it requires further research to evaluate on this aspect.

The efficacies of the hemocoagulase in healing were evaluated on the 3rd and 12th postoperative days. On the 3rd postoperative day smear study was done, and on the 12th day biopsy from the healing sockets for the purpose of histological evaluation were performed randomly in five cases. Histological observations based on the amount of RBC's showed that in side A the count was less compared to side B at the 6th hour postoperatively. A statistically significant difference was observed suggesting that the side 'A' solution had the property of achieving faster hemostasis, thereby promoting wound healing.

Evaluation of polymorphs at 6th hour and 3rd day postoperatively, revealed that there were no significant changes statistically. Thus, suggesting absence of infection on both the sides. With regard to epithelial cells, it was not significant at 6 hours but on the 3rd day the epithelial cells were found to be more in side A. On statistical evaluation the amount of epithelial cells were found to be highly significant on the 3rd day when compared to side B suggesting an augmentation in the healing phase. Regarding chronic inflammatory cells, at 6 hours and on the 3rd day, no significant changes were noted. Thus, suggesting an absence of infection on both the sides. The extractions performed were for orthodontic purpose and the sites were free of infection. This explains for the absence of infection on the postoperative days in the respective sites taken up for the study.

Histological observations following biopsy on the 12th day postoperatively revealed that there was an augmentation of the healing phase in side A when compared to side B. Parameters following the histological observations, such as epithelialization collagen amount and fibroblasts, were found to be more in side A compared to side B. Thus, statistically the changes were significant, thereby suggesting an enhancement in the healing phase in side A.

Hence, it can be said that this sterile hemocoagulase solution produces a promoting action in wound healing. It has been studied and reported that this sterile hemocoagulase solution converts fibrinogen into fibrin and activates factor XIII. Factor XIIIa catalyses the cross-linking of fibronectin and fibrin.[16,17] Fibrin-fibronectin-collagen network serves as a scaffold for granulocyte migration which paves for fibroproliferative phase. Thereby it promotes wound healing by reinforcing biological glue.[1] Thus, it can be inferred that the use of this sterile topical hemocoagulase solution following dental extraction enhances the normal healing process, by achieving faster hemostasis,[18,19] without any infection.

In this study preoperative antibiotics were not used and only analgesics were prescribed. Thus, augmentation in wound healing could be attributed to the action of the hemocoagulase alone. The dental extractions were performed by the same operator using the same technique bilaterally, to avoid any deviation or discrepancy in the study.

CONCLUSION

Thus, it may be concluded that this sterile topical hemocoagulase solution may be advocated in the field of oral and maxillofacial surgery as a hemostatic agent and promoter of wound healing. However, further studies, with large number of cases and different clinical situations should be considered to authenticate the efficacy of this hemocoagulase solution in the practice of oral and maxillofacial surgery.

CLINICAL SIGNIFICANCE

Wound healing plays an important role in the success of any surgical procedure such as extractions, and the hemocoagulase system may act as a hemostatic agent and a promoter of wound healing.

REFERENCES

1. Ramesh KV, Rao MC, Bairy KL, Ramanarayan K, Kulkarni DR. Effects of procoagulants on wound healing. Indian J Exp Biol 1990;28(1):43-45.
2. Shafer WG, Hine MK, Cevy BM, Tomich CE. Healing of oral wounds. A text book of oral pathology, 4th ed. WB Saunders Company 1993:594-595.
3. Nahas L, Kamigutti AS, Barros AR. Thrombin-like and factor X-activator components of Bothrops snake Venoms. Thrombos Haemostas 1979;41:314-327.

4. Borio PG. Coagulation processes and ophidic venoms. Toxicon 1955;6:30-35.
5. Fattahi T, Mohan M, Caldwell GT. Clinical applications of fibrin sealants. J Oral Maxillofac Surg 2004;62(2):218-224.
6. Cattaneo L. Employment of Bothrops jararaca venom as coagulant in ENT surgery. Latin Am Otorhinolaryngol Min 1957;1-10.
7. Ramesh KV, Kulkarni DR, Bairy KL, Ramanarayan K. Effects of Botropase on wound healing. Ind J Surg 1990 May;52(5):218-221.
8. Ricci A. Trial of some hemostatic drugs in tonsillectomy under general anesthesia with intubation. Minerva Med 1968; 59(93):5011-5014.
9. Assael LA. Hemostasis is a shared responsibility. J Oral Maxillofac Surg 2003;61:1377-1378.
10. Al Belasy FA, Amer MZ. IIemostatic effect of n-butylol–2–cyanoacrylate glue in warfarin-treated patients undergoing oral surgery. J Oral Maxillofac Surg 2003;61(12):1405-1409.
11. Zingali RB, Francischetti IM, Carlini CR, Guimaraes JA. Biochemical and pharmacological screening of snake (Bothrops) venoms: characterization of components acting on blood coagulation and platelet aggregation. Braz J Med Biol Res 1988;21(4):763-765.
12. Lee HS, Kim SH, Kim IT. Intraocular infusate with hemocoagulase for the control of bleeding during vitreous surgery. Korian J Ophthalmol 1989 June;3(1):6-10.
13. Parameshwaran TM, Balasubramanian, Sakunthala. Clinical trial on the efficacy of hemocoagulant (Botropase) in coagulation. J Otolaryngol (Bihar) 1982;3:2.
14. Monteiro RQ. Targeting exosites on blood coagulation proteases. An Acad Bras Cienc 2005 Jun;77(2):275-280.
15. Arezzi R. Action of snake Bothrops jararaca venom in the treatment of ophthalmic zona. Minerva Oftalmol 1969 Mar-Apr;11(2):43-47.
16. Hutton RA, Warell DA. Action of snake venom components on the hemostatic system. Blood Rev 1993 Sept;7(3):176-189.
17. Marsh NA. Snake venoms affecting the hemostatic mechanism: a consideration of their mechanisms, practical applications and biological significance. Blood Coagul Fibrinolysis 1994 June;5(3):399-410.
18. Markland FS. Snake venoms and the hemostatic system. Toxicon 1998 Dec;36(12):1749-1800.
19. Mastsui T, Fujimura Y, Titani K. Snake venom proteases affecting hemostasis and thrombosis. Biochem Biophys Acta 2000 March;1477(1-2):146-156.

ABOUT THE AUTHORS

Sachin Aslam (Corresponding Author)

Reader, Department of Oral Surgery, MES Dental College, Malappuram Kerala, India, e-mail: drsachinaslama@gmail.com

PG Francis

Professor and Head, Department of Orthodontics, MES Dental College, Malappuram, Kerala, India

BHS Rao

Professor and Head, Department of Oral Surgery, Yenepoya University of Health Sciences, Mangalore, Karnataka, India

M Ummar

Professor and Head, Department of Oral Surgery, MES Dental College Malappuram, Kerala, India

JK Issac

Professor and Head, Department of Oral Medicine, MES Dental College, Malappuram, Kerala, India

RB Nair

Senior Lecturer, Department of Oral Surgery, MES Dental College Malappuram, Kerala, India