

Diagnosis of pregnancy-associated venous thromboembolism – position paper of the Working Group in Women’s Health of the Society of Thrombosis and Haemostasis (GTH)

Birgit Linnemann¹, Rupert Bauersachs^{2,9}, Hannelore Rott³, Susan Halimeh³, Rainer Zotz⁴, Andrea Gerhardt⁵, Barbara Boddenberg-Pätzold⁶, Bettina Toth⁷, and Ute Scholz⁸

¹ Medical Practice of Angiology and Haemostaseology, Praxis am Grüneburgweg, Frankfurt/Main, Germany

² Klinikum Darmstadt, Klinik für Gefäßmedizin - Angiologie, Darmstadt, Germany

³ Gerinnungszentrum Rhein Ruhr, Duisburg, Germany

⁴ Centrum für Blutgerinnungsstörungen und Transfusionsmedizin, Düsseldorf, Germany

⁵ Blutgerinnung Ulm, Germany

⁶ Nuramed, Gemeinschaftspraxis für Radiologie und Nuklearmedizin, Köln, Germany

⁷ Gynäkologische Endokrinologie und Fertilitätsstörungen, Ruprecht-Karls-Universität Heidelberg

⁸ Zentrum für Blutgerinnungsstörungen, MVZ Labor Dr. Reising-Ackermann und Kollegen, Leipzig, Germany

⁹ Centrum für Thrombose und Hämostase (CTH), Johannes-Gutenberg-Universität, Mainz, Germany

Summary: Pregnancy and the postpartum period are associated with an increased risk of venous thromboembolism (VTE). Over the past decade, new diagnostic algorithms have been established, combining clinical probability, laboratory testing and imaging studies for the diagnosis of deep vein thrombosis (DVT) and pulmonary embolism (PE) in the non-pregnant population. However, there is no such generally accepted algorithm for the diagnosis of pregnancy-associated VTE. Studies establishing clinical prediction rules have excluded pregnant women, and prediction scores currently in use have not been prospectively validated in pregnancy or during the postpartum period. D-dimers physiologically increase throughout pregnancy and peak at delivery, so a negative D-dimer test result, based on the reference values of non-pregnant subjects, becomes unlikely in the second and third trimesters. Imaging studies therefore play a major role in confirming suspected DVT or PE in pregnant women. Major concerns have been raised against radiologic imaging because of foetal radiation exposure, and doubts about the diagnostic value of ultrasound techniques in attempting to exclude isolated iliac vein thrombosis grow stronger as pregnancy progresses. **As members of the Working Group in Women’s Health of the Society of Thrombosis and Haemostasis (GTH), we summarise evidence from the available literature and aim to establish a more uniform strategy for diagnosing pregnancy-associated VTE.**

Key words: Venous thromboembolism, pregnancy, diagnosis, ultrasonography, lung scintigraphy, computed tomography

Epidemiology

VTE is a leading cause of maternal morbidity in the developed world and, in the case of PE, of mortality as well [1]. While the relative risk of VTE is greatly increased during pregnancy compared with that in non-pregnant women, the absolute risk remains low: estimates of the incidence of pregnancy-associated VTE have varied from 1:500 to 1:1500 pregnancies [2–7]. The risk of VTE is approximately 5-fold greater in pregnant women than in non-pregnant women.

Approximately 80 % of pregnancy-associated VTEs are isolated DVTs, and approximately 20 % are PEs or both DVTs and PEs [5]. Although a systematic review reported weighted event rates for DVT of 21.9 %, 33.7 % and 47.6 % for the first, second and third trimesters, respectively [6], a recent study suggested that the risk might in fact increase exponentially over the duration of the pregnancy [7], with 12.4 % of VTEs diagnosed in the first trimester, 15.3 % in the second trimester and 72.3 % in the third trimester. This detailed risk assessment for each gestational week demonstrated a 21-fold increased risk for the last two weeks before delivery [7].

妊娠相关VTE的危险因素

Table I. Risk factors for pregnancy-associated venous thromboembolism (modified after [26, 27])

Pre-existing risk factors 本身存在的危险因素	<ul style="list-style-type: none"> – Previous venous thromboembolism 有VTE史 – Thrombophilia (hereditary or acquired) 血栓形成倾向 (遗传或获得) – Age >35 years old 年龄 > 35 – Obesity (body mass index >30 kg/m²) 肥胖 – Hypertensive disorders of pregnancy 高血压 – Parity ≥3 – Smoking 吸烟 – Gross varicose veins or symptomatic varicosis 严重静脉曲张或有症状的静脉曲张 – Paralysis or paraplegia 瘫痪或半身不遂 – Medical comorbidities, e.g., heart or lung disease, inflammatory bowel disease, inflammatory polyarthropathy, systemic lupus erythematosus, nephrotic syndrome, type I diabetes mellitus with nephropathy, cancer, sickle cell disease 心脏或肺疾病, 肠炎, 多发性关节炎, 系统性红斑狼疮, 肾病综合征, I型糖尿病, 癌症, 镰状红细胞疾病
Obstetric risk factors 产科的危险因素	<ul style="list-style-type: none"> – Multiple pregnancy 多胎 – Pre-eclampsia 产前惊厥 – Caesarean section 剖腹产 – Prolonged labour (>24 hours) 延长收缩 > 24h – Mid-cavity or rotational operative delivery 中腔或旋转手术分娩 – Severe postpartum haemorrhage (PPH) 严重产后出血
Transient or potentially reversible risk factors 暂时的或潜在可逆的危险因素	<ul style="list-style-type: none"> – Assisted reproductive technology (ART), in vitro fertilization (IVF) 辅助生产技术, 体外受精 – Ovarian hyperstimulation syndrome (OHSS) (first trimester) 卵巢过度刺激综合征 – Any surgical procedure in pregnancy or puerperium (e.g., appendectomy, evacuation of retained products of conception [ERPC], postpartum sterilisation) 妊娠和产褥期任何外科手术 – Hyperemesis, dehydration 脱水 – Hospital stay or bed rest/immobility ≥3 days 住院卧床≥3d – Systemic infection (e.g., pneumonia, pyelonephritis, postpartum wound infection) 全身性感染 – Long-distance travel (>4–6 hours) 远距离旅行 > 4-6h

The puerperium is the time of the greatest risk of pregnancy-associated VTE per day. A meta-analysis demonstrated that two thirds of all DVTs occur antepartum, whereas one third are diagnosed postpartum. In contrast, up to 60 % of pregnancy-related episodes of PE occur in the 4 to 6 weeks after delivery [6, 8]. Because the antepartum period is substantially longer than the 6-week postpartum period, the daily risk of VTE is considerably greater following delivery than during pregnancy [6, 8, 9]. The risk increases 10- to 20-fold [7, 10, 11], or possibly even up to 80-fold [12], in the postpartum period. It is high in the first postpartum week, particularly after caesarean section, and decreases afterwards, reaching the non-pregnant level after approximately 6 weeks [4, 7, 12, 13]. However, a modest but still significantly increased risk (odds ratio [OR] 2.2, 95 % confidence interval [CI] 1.5–3.1) has been observed for the period from 7–12 weeks postpartum. The risk was no longer elevated after 12 weeks (OR for the period 13–18 weeks after delivery 1.4, 95 % CI 0.9–2.1; OR for the period 19–24 weeks after delivery 1.0, 95 % CI 0.7–1.4) [10].

Risk factors

VTE during pregnancy is a multicausal disease because it results from the interaction of several different risk determinants. The absolute risk of thrombosis mainly depends upon a personal or family history of VTE and the presence of hereditary and/or acquired thrombophilic risk factors. Because women today often postpone their first pregnancy and women > 45–50 years old can also get pregnant due

to oocyte or embryo donation, age should be considered as an additional VTE risk factor. The identification of risk factors in the individual patient is important when assessing the woman's risk of VTE. Known expositional and dispositional risk factors of VTE are shown in Tables I and II.

A personal history of VTE is a significant risk factor for thromboembolic complications during pregnancy. Women with a previous VTE have recurrence rates of 6 % and 8 % during the antepartum and postpartum periods, respectively [14, 15]. In a prospective study of 125 pregnant women with a single previous episode of VTE, the incidence of recurrence without prophylaxis was 2.4 % antepartum (95 % CI 0.2%–6.9 %) and 2.5 % postpartum (95 % CI 0.5%–7.0 %) [16]. Regardless of the presence or type of thrombophilia, a positive family history of VTE independently increases the risk of VTE 2- to 4-fold [17, 18].

Major hereditary forms of thrombophilia include the G1691A mutation of the factor V gene (factor V Leiden mutation [FVL]), the G20210A mutation of the prothrombin gene (PT) and deficiencies of antithrombin, protein C and protein S. A systematic review analysing data from 9 studies with 2526 patients showed that all of the hereditary thrombophilias markedly increased the risk of pregnancy-related VTE (Tab. II). The greatest increase in risk was observed in the presence of a homozygous FVL or PT mutation, as well as combined heterozygous FVL and PT mutations [19]. Other groups have also emphasised the importance of a hereditary AT deficiency as a high risk thrombophilic disorder, especially during pregnancy [20, 21]. In contrast, the presence of a homozygous methylene tetrahydrofolate reductase (MTHFR) C677T mutation did not contribute to the risk of VTE in pregnant women [19, 22].

Table II. Risk of a first pregnancy-related venous thromboembolism (VTE) in women with hereditary thrombophilia [19, 20]

Thrombophilia	Prevalence, %	Relative risk of VTE, OR (95% CI)	Estimated absolute risk of VTE per 1000 pregnancies*
Factor V Leiden mutation			
Heterozygous	2.0–7.0	8.3 (5.4–12.7)	8
Homozygous	0.2–0.5	34.4 (9.9–120.1)	34
Prothrombin G20210A mutation			
Heterozygous	2.0	6.8 (2.5–18.8)	7
Homozygous	rare	26.4 (1.2–559.3)	26
Factor V Leiden and prothrombin G20210A mutation compound heterozygous	0.18	44 (25–79)	44
Antithrombin deficiency†	<0.1–0.6	4.7 (1.3–17.0)	5
Protein C deficiency	0.2–0.3	4.8 (2.2–10.6)	5
Protein S deficiency	<0.1	3.2 (1.5–6.9)	3

Abbr.: VTE: Venous thromboembolism, OR: Odds ratio, CI: Confidence interval. *Assuming a baseline risk of 1 event per 1000 pregnant patients without any known thrombophilia. †Although data are limited, VTE risk is supposed to be substantially higher in antithrombin-deficient pregnant women and can increase up to 20- to 28-fold, depending on the type and extent of antithrombin deficiency [18, 122–124].

Although not well studied, women with known antiphospholipid syndrome (APS) and previous VTE seem to be at high risk for recurrent VTE during pregnancy. Two retrospective studies identified APS as a risk factor for pregnancy-related VTE (adjusted OR 5.1–15.8) [5, 23]. The risk of VTE in female APS patients with obstetric complications but without previous VTE is unclear, but seems to be low. In a case series of 21 pregnant women without prior VTE but with a diagnosis of primary APS due to obstetric complications, there were no thrombotic events when low-dose anticoagulant therapy was restricted to 3 to 5 days postpartum [24].

Pregnancy-specific VTE risk factors include multiple pregnancies, hyperemesis, pre-eclampsia, prolonged labour and delivery via caesarean section [4, 25–27]. In a Danish nationwide prospective cohort study including 1.3 million pregnancies, obesity, infection and hospitalisation during pregnancy were identified as additional risk factors for VTE during pregnancy and postpartum [28].

Regarding the increased use of assisted reproductive technologies (ART), there have been reports of subsequent venous and arterial thromboembolic complications [29]. The relative risk of ART-related VTE has been demonstrated to be particularly high in the first trimester of pregnancy. A substantial number of venous thrombotic events have been attributed to the presence of ovarian hyperstimulation syndrome (OHSS), which is a recognised complication of ART that occurs in moderate or severe forms in 3–8% of successful *in vitro* fertilisation cycles [25, 29–32]. OHSS, which is accompanied by high oestradiol concentrations, has been correlated with the occurrence of unusual site thrombosis, particularly DVT of the upper extremities and of internal jugular veins [29, 33, 34]. However, despite these established associations, the incidence of VTE in ART remains low, affecting only 0.08–0.11% of treatment cycles [35].

Pathogenesis

Pregnancy is an acquired and independent risk factor for VTE. During pregnancy, the plasma concentrations and activities of several proteins involved in blood coagulation and fibrinolysis change. These alterations typically promote coagulation (e.g., increases in fibrinogen and factors VII, VIII: C and IX, as well as von Willebrand factor), reduce anticoagulation (acquired resistance to activated protein C, decrease in protein S and antithrombin activities), and inhibit fibrinolysis (increase in plasminogen activator inhibitors 1 and 2), thus resulting in a pro-coagulant state that can be considered physiological preparation for the haemostatic challenge of delivery [36–38].

The venous system of the lower extremities is particularly prone to thrombosis due to progesterone-induced venous dilatation and compression of the iliac veins and the inferior vena cava (IVC) by the gravid uterus [39, 40]. Endothelial damage to the iliac veins can occur during normal vaginal, assisted and surgical delivery [41]. In approximately 70% of cases, maternal DVT is located in the left leg [26], and most frequently involves the iliofemoral veins, where it carries a high embolisation risk [41]. Proximal DVT without involvement of the calf veins is frequent (71%), and isolated iliac DVT is reported in 17% of cases [42]. The predisposition to left-sided thrombosis was first perceived and reported by May and Thurner [43] and by Cockett and Thomas [44] more than 40 years ago, and it has been attributed to the compressive effects that the right iliac artery exerts on the left iliac vein by crossing it on the left side.

During ART, controlled ovarian stimulation leads to multiple oocytes and supra-physiological levels of oestrogens, thus resulting in a hypercoagulable state, especially in women with polycystic ovarian syndrome (PCOS) [38]. As a consequence, OHSS has

been identified as a risk factor for first-trimester thrombosis. In addition, several women with PCOS suffer from metabolic syndrome as an additional risk factor. Women with OHSS have been shown to be at particular risk for upper extremity DVT, which most frequently involves the subclavian and internal jugular veins [29, 35]. It has been hypothesised that the predisposition to upper extremity DVT after ART results from the marked increase in oestrogen concentrations in the peritoneal fluid, which is drained via the lymphatic system and the thoracic duct into upper extremity veins [33].

Clinical presentation

The clinical suspicion of VTE in a pregnant woman requires an accurate diagnostic workup to confirm or exclude the diagnosis of DVT or PE. Leg swelling is a frequent finding in pregnancy. However, unilateral, particularly left-sided, leg swelling and a difference in calf circumference of 2 cm or more should raise the suspicion of DVT [45, 46]. Isolated iliac vein thrombosis can be accompanied by pain in the buttocks, groin, flank, or abdomen [19, 47].

PE should be considered, particularly if the woman presents with dyspnoea (87% of cases) and pleuritic chest pain (61% of cases) [48]. Tachycardia, tachypnoea, hypoxaemia, haemoptysis, syncope, coughing, and unexplained hypotension may also be present. The symptoms of PE during pregnancy are the same as in non-pregnant women. Especially in cases of acute onset or worsening, diagnostic imaging studies are warranted. However, shortness of breath, tachycardia and leg oedema are not uncommon in normal pregnancy. Thus, VTE is confirmed in less than 10% of pregnant women with symptoms suggestive of PE or DVT [49].

Diagnostic workup – general considerations

A thorough physical examination is mandatory if a pregnant woman presents with symptoms suggestive of DVT or PE. In cases with symptoms suggestive of PE, blood pressure measurement, arterial blood gas analysis and an electrocardiogram (ECG) should be performed before diagnostic imaging is considered [47]. ECG has been shown to be abnormal in 41% of pregnant women with acute PE. T wave inversion (21% of cases), S1Q3 pattern (15% of cases) and right bundle branch block (18% of cases during pregnancy) have been described as the most common findings. In the same cohort, arterial blood gas analysis revealed hypoxaemia or decreased oxygen saturation in only a minority of patients (prevalence in confirmed PE of 18% and 3%, respectively) [48].

It must be emphasised that, to date, there have been no randomised trials or even prospective studies that have set reference standards for the diagnosis of VTE in pregnant

women [49]. In particular, clinical decision rules in pregnant women with suspected VTE have not yet been developed or prospectively validated. In addition, D-dimer levels usually increase with the progression of pregnancy and can be expected to be greater than the normal range in the majority of normal pregnancies. Diagnostic imaging therefore plays a major role in cases of suspected DVT or PE in pregnancy. If there is a delay in performing objective testing, anticoagulant therapy should be initiated until VTE is objectively confirmed or excluded, unless there are strong contraindications against the use of anticoagulants [18, 50].

Recommendation 1 – A clinical suspicion of pregnancy-associated VTE requires immediate objective testing to confirm or exclude DVT and/or PE. If the probability of VTE is estimated to be high or if there is any delay in obtaining test results, therapeutic doses of low-molecular weight heparin (LMWH) or unfractionated heparin (UFH) should be administered until a definitive decision based on objective test results can be made.

Suspected DVT – imaging studies

Compression ultrasound

Complete compression ultrasound (CCUS) of the entire lower extremity venous system is the method of choice to confirm or exclude DVT in non-pregnant patients [50, 51]. Several studies and a meta-analysis have revealed the high sensitivity of CCUS as a single test for the diagnosis of DVT in non-pregnant patients [52–57]. However, the increased frequency of isolated iliac vein thrombosis during pregnancy, which is more difficult to diagnose using CCUS, requires the modification of diagnostic strategies. If a pregnant woman presents with back or pelvic pain and swelling of the entire leg and if isolated iliac vein thrombosis is suspected (e.g., clinically or due to absent respiration-modulated flow in the common femoral vein), additional imaging is mandatory to assess venous blood flow within the iliac veins by pulsed Doppler technique or by colour-coded duplex ultrasound. However, both false positive and false negative findings are possible due to slow venous flow and extrinsic venous compression and to non-occlusive thrombi and visualisation of collateral flow phenomena, respectively.

Le Gal et al. performed a single complete ultrasound examination extending from the IVC to the calf veins using high resolution B mode ultrasonography with different probes, according to the depth of the examined vessels [58]. The IVC and iliac veins were visualised by duplex ultrasound (i.e., direct imaging and Doppler flow techniques), whereas the femoral, popliteal and calf veins were assessed by CCUS. All of the venous segments were studied across their entire lengths. In addition, the great and small saphenous veins were studied at their junctions with the deep venous system. DVT was diagnosed in 10.5% of

suspected cases. Of the 177 patients without DVT who did not receive anticoagulant therapy, only two had an objectively confirmed DVT over the 3 month follow-up period (1.1%; 95% CI 0.3–4.0%), yielding a negative predictive value (NPV) of 98.2% (95% CI 94.9–99.4%). However, it must be noted that, in their study, the ultrasound examinations were performed by physicians with at least 10 years of experience in vascular ultrasound imaging. Their data were in agreement with those of a retrospective cohort study performed by the same study group in pregnant and postpartum patients [59]. Another prospective cohort study performed in 4 Canadian centres included 221 pregnant women with a suspected DVT [60]. All of the patients underwent compression ultrasound of the femoral and popliteal veins up to the calf trifurcation and duplex ultrasound of the external iliac vein. In 16 patients (7.2%), DVT was diagnosed at the initial presentation or during serial testing between days 2–4 and 6–8. In patients with negative ultrasound, anticoagulation was withheld. The reported risk of VTE within a clinical follow-up period of 3 months during ongoing pregnancy or at least 6 weeks after delivery was 0.49% (95% CI 0.09–2.71%). A sensitivity of 94.1% (95% CI 69.2–99.7%) and an NPV of 99.5% (95% CI 96.9–100%) were calculated. These findings were consistent with those previously published by the same study group [61]. However, all of these studies had important limitations, and their quality was considered low to moderate [50].

Recommendation 2 – Ultrasonography, including CCUS of the lower extremity veins and duplex ultrasound of the iliac veins, is recommended as the method of choice for pregnant women with a clinical suspicion of DVT. Because the iliac veins are increasingly difficult to assess with increasing gestational age, ultrasound examinations should be performed by an experienced sonographer. It is important to note that Doppler techniques, which indicate the absence of venous blood flow or demonstrate thrombus material in the iliac veins, might yield false positive, as well as false negative, results. If ultrasonography is negative or inconclusive, clinical follow-up, serial ultrasound examinations (e.g., on days 3 and 7), D-dimer testing and/or magnetic resonance (MR) venography without contrast enhancement should be considered. A diagnostic algorithm to confirm or exclude DVT is suggested in Figure 1.

Magnetic resonance venography

MR venography, which does not involve radiation exposure, has high sensitivity and specificity for the diagnosis of iliac vein thrombosis in non-pregnant patients. MR venography has therefore been suggested as an alternative imaging modality in pregnant patients with suspected isolated iliac DVT in whom the diagnosis cannot be confirmed by ultrasonography. To date, there have only been limited data with regard to the safety of MR venography during organogenesis, but MR imaging techniques without contrast enhancement seem to be safe, especially after the first trimester [62, 63]. Gadolinium has been shown to cross the foetal blood-placental barrier and appear in the foetal bladder and the amniotic fluid, where it can be swal-

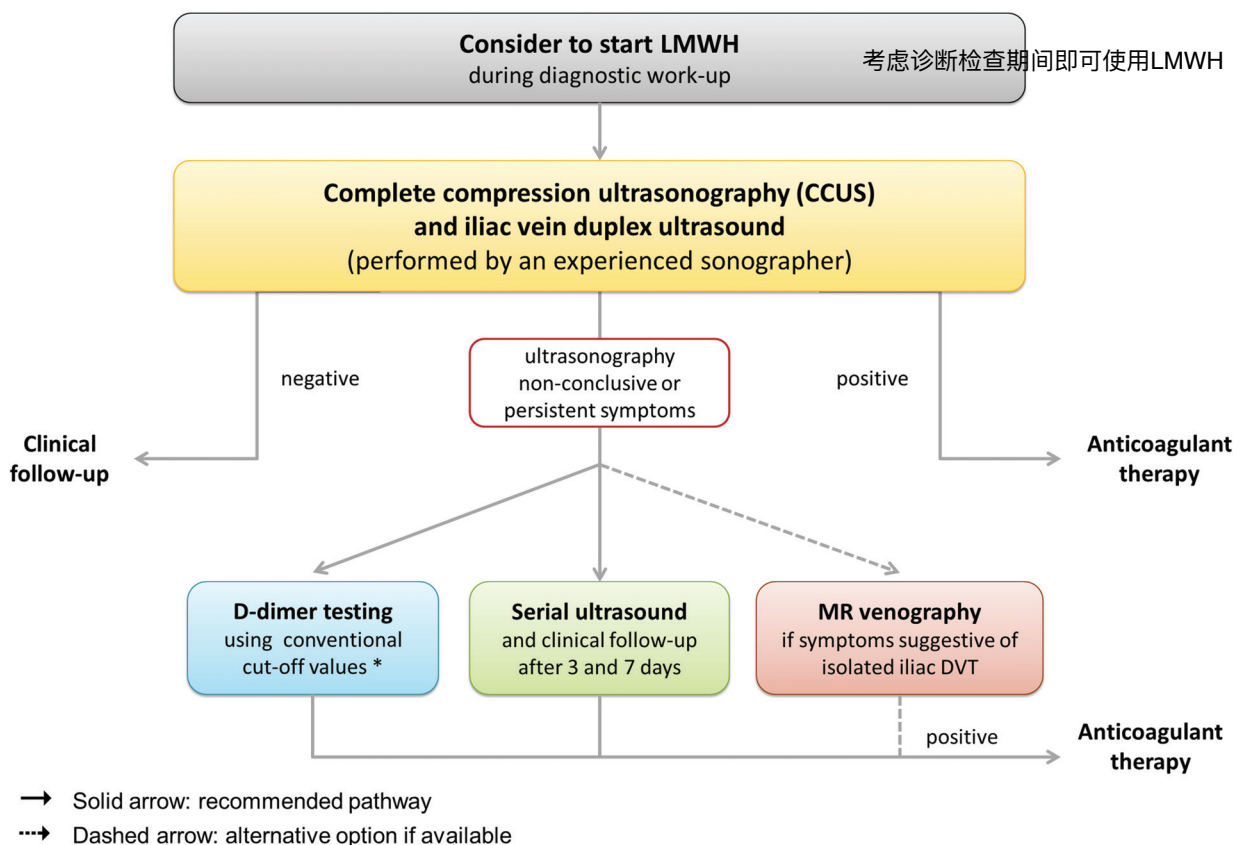


Figure 1. Diagnostic algorithm for pregnancy-associated deep vein thrombosis.

http://econtent.hogrefe.com/doi/pdf/10.1024/0301-1526/a000503 - Admin User_Predefined <customer@atypoon.com> - Tuesday, June 21, 2016 8:36:13 PM - IP Address: 218.94.80.146

lowed and reabsorbed by the foetus [63, 64]. Animal studies have revealed teratogenic effects, but only at markedly increased and repeated doses. However, no harmful effects have been reported in human foetuses to date [65, 66]. Because the half-life of gadolinium in the foetus is not known, gadolinium should be used with extreme caution during pregnancy and only if the potential maternal benefits clearly outweigh the risks to the foetus [63, 64].

Pelvic MR venography can be performed using flow-sensitive or time-of-flight sequences, thereby avoiding the use of gadolinium [63]. In comparison with conventional venography in non-pregnant patients, these techniques have a sensitivity of 100% and a specificity of 94% [67]. A two-centre trial compared MR imaging without contrast enhancement in a time-of-flight technique for ultrasonography in 27 pregnant patients between the 23rd and 39th weeks of gestation [68]. Three cases (11.1%) of iliac vein thrombosis were missed on ultrasound but detected with MR venography. In 20 of 27 cases (74%), MR imaging found a more proximal thrombus extension than ultrasonography. MR venography seems to allow for a more detailed depiction of thrombus extension and might therefore be considered a complementary technique in cases of initial negative ultrasound findings in pregnant patients suspected of having isolated iliac DVT [68, 69]. However, concerns remain about the potential risks of heating effects from radio frequency pulses and the effects of acoustic noise on the foetus [63, 70, 71].

Recommendation 3 – If the clinical presentation raises suspicions of isolated iliac vein thrombosis and if ultrasonography is non-diagnostic, MR venography can confirm or exclude iliac vein thrombosis. Due to potential foetal risks (e.g., gadolinium toxicity, acoustic noise), MR imaging should be used very restrictively throughout pregnancy and, if indicated, without gadolinium contrast.

Conventional and CT venography

Traditionally, conventional venography has been considered to be the standard test for the diagnosis and exclusion of DVT, although in clinical practice, this method has been widely replaced by ultrasonography [50]. Computed tomographic (CT) venography can be a useful adjunct in suspected iliac vein thrombosis in non-pregnant patients, but it carries much higher radiation exposure for the foetus than conventional venography and should therefore be avoided during pregnancy [72, 73].

Suspected PE – imaging techniques

Echocardiography and CCUS of the lower extremities

Echocardiography does not involve exposure to radiation, and is easy to perform; in addition, it can be repeated as

often as needed without any harm to the foetus, which is why it has become an important diagnostic tool during pregnancy and is the preferred screening method with which to assess cardiac function [47]. If available, it can be performed in the emergency unit preceding or following bilateral ultrasound examination of the lower extremities. A suspicion of PE is substantiated if echocardiographic signs of acute right heart strain (i.e., severe tricuspid regurgitation, right ventricular dilatation or hypokinesis without RV wall hypertrophy) are present.

Although there has been no direct evidence from trials for the use of bilateral lower extremity CCUS in cases of suspected PE in pregnant women, an ultrasound examination in the early phase can be helpful. Because therapeutic approaches in patients with confirmed DVT and PE are essentially the same, it is recommended to start anticoagulant therapy at the time of diagnosis of DVT without further radiologic imaging for PE confirmation. If CCUS is negative or inconclusive, radiologic imaging is required.

Recommendation 4 – In cases of clinically suspected PE, echocardiography and ultrasound examination of the lower extremities should be considered as initial imaging methods to substantiate the suspicion of PE and confirm the diagnosis of DVT, respectively.

Lung scintigraphy or CT scan

The latest version of the ESC guidelines for the management of PE states that lung scintigraphy might be preferred over CT pulmonary angiography (CTPA) because it avoids the high radiation dose that CTPA inflicts on the female breast and the resulting small but significant increase in the lifetime risk of breast cancer [74]. A chest radiograph can be considered as first imaging study, particularly in cases in which other differential diagnoses (e.g., pneumonia or pneumothorax) are at least as likely as PE [49, 75, 76]. The classic radiographic signs of PE – a peripheral wedge-shaped infiltrate (Hampton's hump) and decreased pulmonary vascularity (Westermarck's sign) – are rare findings. However, the radiation dose to the foetus from chest radiography at any stage of pregnancy is negligible, and chest radiography can guide the decision towards or away from further imaging studies [77]. Women with a normal chest radiograph should undergo lung scintigraphy to diagnose or exclude PE because this imaging modality allows for minimisation of maternal radiation exposure. In women with an abnormal chest radiograph or known pulmonary disease that is likely to impair the interpretation of lung scintigraphy, CTPA can be chosen as the primary imaging technique.

In general, approximately 70% of perfusion scans are normal, and another 5–10% lead to a diagnosis of PE, which indicates that a ventilation scan is dispensable in the majority of cases, further limiting radiation exposure. A normal perfusion scan and a negative CT scan have been demonstrated to be equally reliable in excluding PE in pregnant women [78, 79]. This finding has been attributed to a lower frequency of non-diagnostic lung scintigraphy

Table III. Diagnostic value of CT pulmonary angiography versus lung scintigraphy

Study	N	Study Design	Outcome	Comment
Ridge, 2009 [80]	28 CT scans vs. 25 scintigraphs	Retrospective	PE: 2/42 (4.8%); Diagnostic inadequacy 35.7% vs. 2.1%; $p < 0.001$	Transient interruption of contrast medium by unopacified blood from the IVC in 8/10 non-diagnostic CT scans
Revel, 2011 [84]	46 CT scans vs. 91 scintigraphs	Retrospective, 3-month FU	PE: 13/129 (13.2%); Diagnostic inadequacy 18.6% vs. 18.7%; $p = 0.99$	Better inter-observer agreement for CT ($\kappa = 0.75$; 95% CI 0.63 – 0.87) than for scintigraphy ($\kappa = 0.75$; 95% CI 0.63 – 0.87)
Shahir, 2010 [85]	106 CT scans vs. 99 scintigraphs	Retrospective, 3-month FU	PE: 4/196 (2.0%); Diagnostic inadequacy 5.6% vs. 3.0%; $p = 0.50$	Negative predictive value (NPV) 99% for CT vs. 100% for scintigraphy
Cahill, 2009 [86]	108 CT scans vs. 196 scintigraphs	Retrospective	PE: 18/260 (6.9%); Diagnostic inadequacy 17.0% vs. 13.2%; $p = 0.38$	In case of a normal chest x-ray, the rate of a non-diagnostic CT scan was 5.3-fold higher than with scintigraphy (95% CI 2.1 – 13.8)
Overall	288 CT scans v. 411 scintigraphs		Diagnostic inadequacy 11.4% vs. 14.9%	

Abbr.: CT: Computed tomography, PE: Pulmonary embolism, FU: Follow-up.

and a higher frequency of non-conclusive CT scans during pregnancy, compared to the non-pregnant population [80–82]. The results of studies comparing the diagnostic adequacy of lung scintigraphy and CTPA are summarised in Table III.

Pregnant women are generally younger and are less likely to have comorbidities affecting the lungs, which would lower the validity of lung scintigraphy. Two studies including 105 and 24 pregnant women with suspected PE reported definite diagnostic scans in 94% and 96% of cases with normal initial chest radiography, respectively [80, 82]. Regarding CTPA, the hyperdynamic effects of pregnancy, which include increases in cardiac output, vascular resistance, heart rate and plasma volume, can lead to a dilution of contrast agent and possibly to an interruption of the contrast bolus when opacified blood from the superior vena cava is mixed with unopacified blood from the IVC, which can result in poor opacification of the pulmonary arteries [49, 80, 81, 83]. Furthermore, pressure in the IVC is increased by the gravid uterus, especially in the supine position, and there is a significant increase in IVC blood flow during deep inhalation. Technically inadequate and therefore non-diagnostic CTPA examinations have been reported in 6–36% of cases [80, 84–86]. Therefore, CTPA protocols must consider the haemodynamic changes that occur during pregnancy and should be adapted to improve image quality (e.g., avoidance of initial deep inhalation, automated bolus tracking, a short scan delay, high iodine flux achieved by high flow rate of contrast medium and/or high iodine concentration) [49, 83]. In addition, adequate low-dose strategies for both lung scintigraphy and CTPA should be used while maintaining diagnostic quality [49].

The serious adverse effects of *in utero* radiation exposure include teratogenicity and oncogenicity. However, the potential risks of exposure to ionising radiation must be balanced against the risk of missing a potentially fatal condition, such as PE. In contrast, clinical suspicion of PE without confirmation by adequate imaging studies can ex-

pose the mother and foetus to the risks of anticoagulant treatment and can influence management strategies at the time of delivery, as well as in future pregnancies. Therefore, the diagnosis or exclusion of PE by means of appropriate diagnostic methods, including radiologic imaging, is crucial [74].

Foetal radiation exposure

The average dose from naturally occurring background radiation over the course of a normal gestation is 0.5–1.0 mSv. Exposure to radiation doses lower than 50 mSv has not been shown to be associated with different pregnancy outcomes, compared with foetuses exposed to background radiation alone [49, 87, 88]. Within the first two weeks after conception, a foetal radiation dose of 50–100 mSv can cause the failure of blastocyst implantation, resulting in spontaneous miscarriage [63]. If the embryo survives, exposure to radiation in this early phase will probably not result in deterministic or stochastic effects on the foetus because blastocyst cells are omnipotent and can replace damaged cells (the so-called “all-or-none period”). The growing embryo or foetus is most vulnerable to radiation effects between the 8th and 15th weeks of gestation [89]. A definitive threshold has not been determined, but it is assumed that the risks of congenital malformations, intrauterine growth restriction, intellectual disability, and pregnancy loss substantially increase with doses greater than 100–200 mSv [63, 87].

The amounts of radiation absorbed by the foetus during different diagnostic tests are shown in Table IV. It is important to note that all radiologic imaging tests fall well below the critical threshold of 100–200 mSv. Furthermore, the effects of radiation on the foetus depend not only on the radiation dose applied to the mother but also on the gestational age at which exposure occurs. For example, if CTPA is performed because of suspected PE in the mother, the foetus is exposed to scatter radiation. In early pregnancy, the distance from the directly irradiated region to the embryo is at least

Table IV. Foetal and maternal radiation doses associated with diagnostic tests for VTE. The broad ranges of values for some tests reflect heterogeneity in the protocols and equipment used, as well as differences in the size and age of the foetus at time of exposure [74, 89]

Imaging technique	Foetal exposure (mSv)	Maternal exposure (mSv)
Chest x-ray (two views)	0.001–0.01	<0.01
Ventilation lung scan ^{99m} Tc	0.1–0.3	<0.01
Low-dose perfusion lung scan ^{99m} Tc	0.1–0.6	0.2–1.2
CT pulmonary angiography	0.01–0.66	7–70
Conventional pulmonary angiography	2.2–3.7	15–20
Conventional venography	3–6	0.5–2
CT venography of the iliac veins	10–50	10–50

Abbr.: mSv: millisievert, Tc: Technetium, CT: Computed tomography

20 cm, and scatter radiation levels have been estimated to be no more than 1% of the chest dose [90]. With the progression of pregnancy, foetal radiation exposure will increase because the growing foetus moves closer to the imaging volume. Perfusion scintigraphy requires intravenous injection of a radionuclide tracer, usually ^{99m}Tc-labelled microalbumin particles, leading to perfusion-dependent and bladder reservoir-related direct foetal exposure. It remains a matter of debate whether CTPA or lung scintigraphy provides exposure to a lower foetal radiation dose. Dose estimates depend on additional factors, e.g. the type and model of scanner, the imaging protocol and the methods used to estimate radiation exposure. In conclusion, the radiation dose that is likely to result from any diagnostic procedure should present no risk of foetal death, malformation, growth retardation or impairment of mental development.

However, according to the currently accepted linear no-threshold models, which hypothesise that ionising radiation can cause cancer at any dose, a stochastic risk of carcinogenesis after *in utero* radiation exposure always remains. Leukaemia has been described as the most common radiation-associated malignancy in childhood [91]. The risk of cancer is difficult to predict, particularly if radiation doses are very low. The International Commission on Radiological Protection has estimated the increase in the risk of fatal childhood cancer before the age of 15 years old after *in utero* radiation exposure to be approximately 0.006% per mSv, which corresponds to a risk of one in 17,000 cases per mSv [88]. With higher doses (e.g., 20–50 mSv during pelvic CT), there is an estimated 2-fold increased risk of childhood cancer, but the absolute increase in lifetime cancer risk remains low and has been estimated to be less than one in 250 cases [63, 89]. Considering that approximately 23–42% of the general population can be expected to develop cancer in their lifetime, the impact of *in utero* radiation exposure due to diagnostic imaging on lifetime cancer risk seems to be negligible [63, 87]. A population-based study of 1.8 million mother-child pairs in Ontario (Canada) did not reveal a significant increase in the risk of cancer in children of mothers who underwent CT or radionuclear imaging during pregnancy compared with children born to mothers with no ex-

posure (adjusted hazard ratio 0.68; 95% CI 0.25–1.80), although small harmful effects could not be excluded [91]. Moreover, the overall risk of radiologic imaging seems to be small in comparison with the natural risks of pregnancy: 15% risk of spontaneous miscarriage, 4% risk of prematurity and growth retardation, 3% risk of spontaneous birth defects, and 1% risk of mental retardation [63, 90].

Maternal radiation exposure

Lung cancer and breast cancer are the two malignancies that account for the greatest risk of radiation-induced cancer mortality in exposed women [49]. The proliferating glandular breast tissue is assumed to be especially sensitive to radiation [92, 93], and CTPA exposes maternal breasts to a much higher radiation dose than lung scintigraphy (Table IV). It has been estimated that exposure of the breasts of women aged 35 years old to 10 mSv increases the risk of breast cancer by approximately 14% over the background rate for the general population [94]. The lifetime excess relative risk of breast or lung cancer in girls and young women undergoing a single CTPA examination has been calculated to be 1.7–5.5% [95]. Although the risk resulting from an individual CTPA or lung scintigraphy is low, it should be considered that a substantial number of patients will undergo repetitive examinations for PE or other reasons during their lifetimes. To minimise the oncogenic and teratogenic risk of radiation for the mother and the foetus, all medically imposed radiation doses must therefore be kept “as low as reasonably achievable” (the ALARA principle). Pregnant patients should also be well hydrated and should be asked to urinate frequently to excrete the radionuclide after lung scintigraphy.

Iodinated contrast agents

Small amounts of iodinated contrast agents can cross the placenta and enter the foetal circulation and the amniotic fluid, exposing the foetus to additional risks [66]. No effect on foetal thyroid function has ever been reported, but a theoretical risk of iodine-induced neonatal hypothyroidism remains [49, 89, 96, 97]. Although it is standard practice to screen all neonates for hypothyroidism, this test is particularly important in neonates born to women who re-

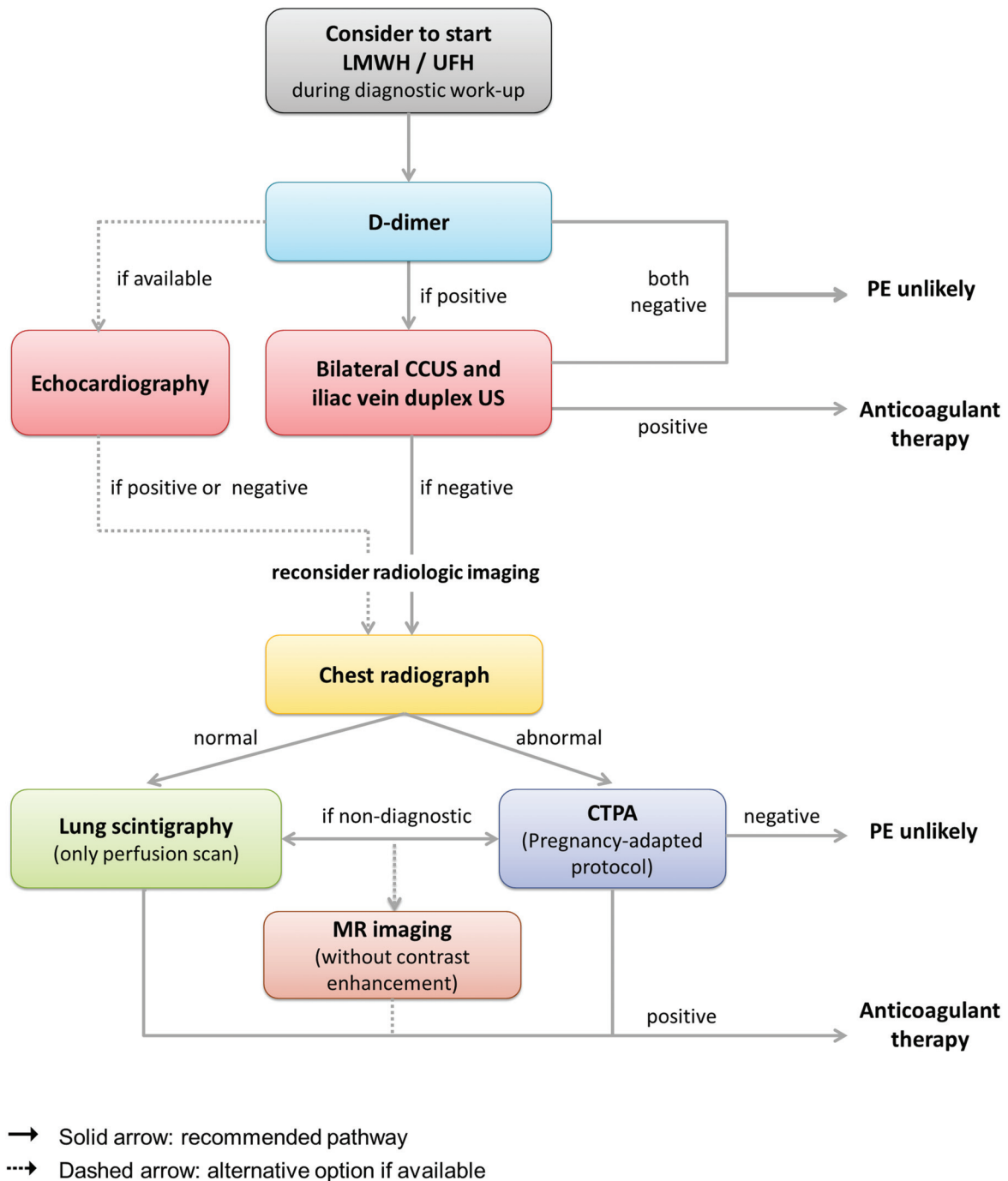


Figure 2. Diagnostic algorithm for pregnancy-associated pulmonary embolism.

ceived iodinated contrast agents during pregnancy [98]. No animal studies have demonstrated the teratogenicity of intravascular administration of iodinated contrast media, but the current guidelines of the European Society of Urogenital Radiology (ESUR) state that iodinated contrast agents should be administered with caution because serious adverse effects cannot be definitively excluded [98].

Less than 1% of contrast medium administered to lactating women is excreted into the breast milk, and less than 1% in the breast milk is absorbed by the child [99]. Theoretical risks from contrast agents include direct toxicity or allergic sensitivity and reaction, neither of which has been reported [63, 89].

MR imaging

The limitations of CTPA and concerns about the potential harmful effects of ionising radiation techniques and iodinated contrast agents during pregnancy led to the consideration of the benefits of the use of MR imaging for suspected PE in pregnant patients. MR imaging detects central and segmental emboli accurately, but it has been less suited for detecting smaller subsegmental emboli. However, no management studies have evaluated the performance of MR pulmonary angiography for PE in pregnancy to date [49, 100]. If MR pulmonary angiography is considered, pregnant women should undergo non-

enhanced MR imaging with protocols using motion-resistant bright blood techniques that do not require intravenous contrast material (e.g., balanced steady-state free precession [SSFP] imaging) [101]. These techniques can visualise central, lobar and segmental arteries and provide sufficient image quality. Kluge et al. presented promising results of real-time MR imaging without gadolinium contrast in 62 non-pregnant patients with suspected PE, demonstrating a sensitivity of 85 % and specificity of 98 % with this technique [100]. Although the use of MR imaging has not been shown to have deleterious effects on the foetus, these techniques should be indicated restrictively throughout pregnancy (see MR venography).

Conventional pulmonary angiography

Percutaneous catheter-based pulmonary angiography has been generally replaced by CTPA and lung scintigraphy and is not typically performed in pregnant patients. If unavoidable, e.g. if life-threatening PE is suspected, angiography via the brachial route should be preferred over femoral access because the former exposes the foetus to less radiation (0.5 mSv vs. 2.2–3.7 mSv) [102].

Recommendation 5 – If lung scintigraphy is available, a low-dose perfusion scan is the preferred imaging technique to diagnose or exclude pregnancy-associated PE in women with normal chest radiography because this method exposes maternal breasts to less radiation than CTPA. If an initial chest radiograph is abnormal or if lung scintigraphy is non-conclusive or not available, CTPA should be prioritised. Foetal and maternal radiation doses with either lung scintigraphy or CTPA are far lower than the critical threshold of 50 mSv. Therefore, neither test should be withheld categorically from pregnant women who present with a clinical suspicion of PE. A suggested diagnostic algorithm to confirm or exclude PE is presented in Figure 2. Local diagnostic protocols should be adapted according to the availability of imaging techniques and the examiner's experience.

Clinical pre-test probability

A recent review and meta-analysis showed that the diagnosis of VTE was confirmed in only 4.1% of pregnant women, compared with 12.4% of non-pregnant patients who presented in the emergency unit with the clinical suspicion of PE [103]. To limit the number of radiologic imaging studies in pregnant women, clinical prediction rules, which are an integral part of diagnostic management in the non-pregnant population, might also be desired for pregnant women with suspected VTE. However, studies that established clinical prediction rules, such as the Wells or Geneva scores, excluded pregnant women, and these rules have not yet been validated for use in pregnancy [104–106]. Because pregnant women frequently develop leg swelling or dyspnoea unrelated to DVT or PE, and are less likely to have comorbidities included as risk factors in these models, these scores might not be applicable during pregnancy and cannot be recommended [50].

O'Connor et al. published a retrospective analysis of 125 pregnant women who were referred for CT angiography [107], whereas Cutts et al. retrospectively investigated 183 pregnant patients who underwent ventilation perfusion scanning for suspected PE [108]. In both studies, no patients with a Wells score of less than 6 points had confirmed PE, corresponding to sensitivity and an NPV of 100% [107, 108]. Further prospective evaluation of this clinical prediction model is required.

In a multicentre study, Chan et al. assessed 11 variables including Wells score [104] to identify the most appropriate variable for prediction of the presence or absence of DVT in 194 unselected pregnant women with a suspected first DVT [45]. In their final model, the authors suggested a prediction model based on three variables, i.e., symptoms in the left leg (L), calf circumference difference ≥ 2 cm (E for oedema), and first trimester (FT) presentation (together constituting the so-called "LEFT score"). If a pregnant woman with suspect-

Table V. D-dimer values according to the duration of pregnancy. In all of the cited studies, the threshold for positive D-dimer was 500 mg/nL

Study group	D-dimer test	Study participants	1 st trimester	2 nd trimester	3 rd trimester
Morse, 2004 [111]	IL-test D-dimer (IL)	N = 48, Healthy women	Mean: 191 Range: 45–553	Mean: 393 Range: 142 – 2210	Mean: 544 Range: 155 – 2782
Kline, 2005 [110]	MDA immunoturbidometric assay (Organon Teknika)	N = 50, Healthy women	Mean \pm SD: 579 \pm 363 Normal D-dimer: 50 %	Mean \pm SD: 832 \pm 425 Normal D-dimer: 23 %	Mean \pm SD: 1159 \pm 573 Normal D-dimer: 0 %
Kovac, 2010 [118]	HemosIL D-dimer HS (IL)	N = 89, Healthy women	Mean \pm SD: 222 \pm 64 Range: 121 – 474 Normal D-dimer: 84 %	Mean \pm SD: 326 \pm 131 Range: 171 – 333 Normal D-dimer: 33 %	Mean \pm SD: 475 \pm 169 Range: 206 – 890 Normal D-dimer: 1 %
		N = 12, Confirmed DVT	Mean \pm SD: 1596 \pm 95 Range: 1500 – 1691	Mean \pm SD: 1330 \pm 700 Range: 524 – 1784	Mean \pm SD: 1157 – 374 Range: 922 – 1818
Wang, 2013 [119]	Latex-based immunoturbidimetry (Diagnostica Stago)	N = 1343 Healthy women	IQR: 200 – 410 Normal D-dimer: 85 %	IQR 470 – 1030 Normal D-dimer: 29 %	IQR: 910 – 1870 Normal D-dimer: 4 %

Abbr.: SD: Standard deviation, IQR: Interquartile range.

Table VI. Diagnostic methods for venous thromboembolism during pregnancy

Diagnostic method	Advantages	Disadvantages
Lower extremity CCUS/and iliac vein duplex US	<ul style="list-style-type: none"> – Readily available – Non-invasive – No radiation exposure – Accurately diagnoses LE-DVT allowing anti-coagulant therapy 	<ul style="list-style-type: none"> – Operator-dependent – Might miss isolated iliac vein thrombosis – Negative US requires additional imaging
Chest radiograph	<ul style="list-style-type: none"> – Low radiation dose – Can yield alternative diagnoses – Guides choice of further imaging 	<ul style="list-style-type: none"> – Lack of specificity when normal or when parenchymal or pleural abnormalities are detected
Lung scintigraphy	<ul style="list-style-type: none"> – Lower radiation exposure to maternal breast than CTPA – High sensitivity and NPV in case of a normal chest radiograph – Diagnostic alternative in cases of allergy to iodine or renal failure 	<ul style="list-style-type: none"> – Non-diagnostic in ≈10-15% of cases, e.g., in patients with pre-existing lung disease – Cannot provide differential diagnoses
CT pulmonary angiography	<ul style="list-style-type: none"> – Widespread availability – Rapid image acquisition – Direct visualisation of clot burden – Provides prognostic information by assessing the right to left ventricular ratio (RV/LV) as an indicator of right heart strain – Can yield alternative diagnoses 	<ul style="list-style-type: none"> – Requires iodinated contrast material – Maternal and foetal radiation exposure – Hyperdynamic circulation in pregnancy might increase the rate non-diagnostic imaging
MR pulmonary angiography/ MR venography	<ul style="list-style-type: none"> – Alternative if CT/scintigraphy is contraindicated – No exposure to iodinated contrast or radiation – High sensitivity and specificity to detect pelvic DVT in non-pregnant patients 	<ul style="list-style-type: none"> – Limited availability – Limited ability to detect segmental and sub-segmental PE – Concerns about foetal safety (e.g., gadolinium, acoustic noise) – Non-enhanced MR methods are required, but have less been evaluated
D-dimer testing	Negative D-dimers make clinically important VTE very unlikely	Elevated D-dimers in the majority of cases in the 2nd and 3rd trimesters

ed DVT presented with none of these three variables, DVT was not diagnosed [45, 46]. However, this model requires confirmation in the form of larger prospective studies.

D-dimer testing

D-dimers, which are a degradation product of cross-linked fibrin, have been established as a sensitive but non-specific marker for clinically important VTE. **Whereas a positive test result does not necessarily indicate VTE, a negative test result can be helpful in the exclusion of DVT and particularly of PE.** Guideline recommendations about D-dimer testing during pregnancy have been controversial [27, 49, 74]. During an uncomplicated pregnancy, there is a steady increase in D-dimer levels with a peak on the first day after delivery [38, 109-111]. Multiple pregnancies [112, 113], pregnancy complications (e.g., pre-eclampsia, abruptio placentae, pre-term labour, OHSS) [112, 114, 115] and FVL mutation [116] have been demonstrated to increase D-dimer levels further during pregnancy. **An increase in D-dimer values throughout pregnancy has also been observed in women receiving LMWH at prophylactic or therapeutic doses** [117].

Because of the increasing frequency of false positive test results, D-dimer testing is deemed to be less useful in preg-

nant women than in non-pregnant women. Whereas in the first trimester, 50–85% of pregnant women have normal D-dimer levels, the proportion of women with values within the reference range decreases to 23–33% in the second trimester and to 0–4% in the third trimester [110, 118, 119]. Table V summarises the D-dimer ranges in recent studies sorted by trimester. Pregnant women with confirmed VTE have much higher D-dimer levels than pregnant women without VTE, and pregnancy-specific threshold values for each trimester have been suggested on this basis [111, 113, 118, 120, 121]. Currently, several different D-dimer tests – stratified as moderately sensitive or highly sensitive – are available, and test results vary depending on the different assays in use. Chan et al. investigated the characteristics of five D-dimer assays in 228 pregnant women with clinical suspicion of DVT [120]. Comparing those 15 women in whom DVT was confirmed with DVT-negative subjects, the authors were able to provide cut-off values with an NPV of at least 98% and specificity of at least 60% for each trimester. These findings are promising, but the small sample size and low prevalence of VTE in this cohort represent the limitations of this study. The clinical utility of higher cut-off values therefore must be tested in larger prospective management studies. However, if the conventional reference range adopted from non-pregnant patients is applied, normal D-dimers exclude clinically relevant VTE, and particu-

从使用预防或治疗剂量的妊娠妇女中检测到D-二聚体的值贯穿整个妊娠过程是上升的

larly PE, in pregnant women as reliably as in the non-pregnant population [47, 74].

Recommendation 6 – Because D-dimer levels physiologically increase during pregnancy and peak at delivery, a negative D-dimer test result will become less likely in pregnant women. However, using the conventional reference ranges of non-pregnant individuals, a normal D-dimer test excludes VTE with the same likelihood in pregnant women. To date, reliable pregnancy-specific higher cut-off values have not been provided, but they warrant further investigation.

Conclusions

Pregnant women are at greater risk for VTE than the non-pregnant population. Their risk is substantially increased during the postpartum period, and it is particularly high in women with a previous venous thromboembolic event, a positive family history of VTE or known thrombophilia. Typical clinical signs (e.g., leg swelling, dyspnoea) are non-specific and not uncommon during normal pregnancy. If a pregnant woman is clinically suspected of having VTE, objective testing to diagnose DVT or PE is mandatory. Adequate imaging studies with adapted protocols are the cornerstone of diagnosis of pregnancy-related VTE. CCUS of the lower extremity veins and duplex ultrasound of the iliac veins are the methods of choice for diagnosing DVT during pregnancy and postpartum, whereas lung scintigraphy and CTPA are recommended for the confirmation or exclusion of clinically important central and segmental emboli in the lungs. Advantages and disadvantages of each diagnostic tool are summarised in Table VI. Foetal radiation exposure and contrast-related side effects remain major concerns, but it must be emphasised that radiologic imaging can be used in pregnancy as long as an effort is exerted to achieve the lowest radiation doses possible. All imaging techniques show pregnancy-specific limitations that should be considered in planning a diagnostic strategy for an individual patient.

Abbreviations

APS	Antiphospholipid syndrome
ART	Assisted reproductive technologies
CCUS	Complete compression ultrasonography
CI	Confidence interval
CT	Computed tomography
CTPA	CT pulmonary angiography
DVT	Deep venous thrombosis
ECG	Electrocardiogram
FVL	Factor V Leiden mutation
IVC	Inferior vena cava
LMWH	Low-molecular weight heparin
MR	Magnet resonance
MTHFR	Methylene tetrahydrate folate reductase
NPV	Negative predictive value
OHSS	Ovarian hyperstimulation syndrome
OR	Odds ratio
PCOS	Polycystic ovarian syndrome
PE	Pulmonary embolism
PT	Prothrombin
UFH	Unfractionated heparin
VTE	Venous thromboembolism

References

1. Bourjeily G, Paidas M, Khalil H, et al. Pulmonary embolism in pregnancy. *Lancet* 2010; 375: 500–512.
2. Abdul Sultan A, Tata LJ, Grainge MJ, et al. The incidence of first venous thromboembolism in and around pregnancy using linked primary and secondary care data: a population based cohort study from England and comparative meta-analysis. *PLoS One* 2013; 8: e70310.
3. Kane EV, Calderwood C, Dobbie R, et al. A population-based study of venous thrombosis in pregnancy in Scotland 1980-2005. *Eur J Obstet Gynecol Reprod Biol* 2013; 169: 223–229.
4. Heit JA, Kobbervig CE, James AH, et al. Trends in the incidence of venous thromboembolism during pregnancy or postpartum: a 30-year population-based study. *Ann Intern Med* 2005; 143: 697–706.
5. James AH, Jamison MG, Brancazio LR, et al. Venous thromboembolism during pregnancy and the postpartum period: incidence, risk factors, and mortality. *Am J Obstet Gynecol* 2006; 194: 1311–1315.
6. Ray JG, Chan WS. Deep vein thrombosis during pregnancy and the puerperium: a meta-analysis of the period of risk and the leg of presentation. *Obstet Gynecol Surv* 1999; 54: 265–271.
7. Virkus RA, Løkkegaard EC, Bergholt T, et al. Venous thromboembolism in pregnant and puerperal women in Denmark 1995-2005. A national cohort study. *Thromb Haemost* 2011; 106: 304–309.
8. Gherman RB, Goodwin TM, Leung B, et al. Incidence, clinical characteristics, and timing of objectively diagnosed venous thromboembolism during pregnancy. *Obstet Gynecol* 1999; 94: 730–734.
9. Simpson EL, Lawrenson RA, Nightingale AL, et al. Venous thromboembolism in pregnancy and the puerperium: incidence and additional risk factors from a London perinatal database. *BJOG* 2001; 108: 56–60.
10. Kamel H, Navi BB, Sriram N, Hovsepian DA, et al. Risk of a thrombotic event after the 6-week postpartum period. *N Engl J Med* 2014; 370: 1307–1315.
11. Sultan AA, West J, Tata LJ, et al. Risk of first venous thromboembolism in and around pregnancy: a population-based cohort study. *Br J Haematol* 2012; 156: 366–373.
12. Pomp ER, Lenselink AM, Rosendaal FR, et al. Pregnancy, the postpartum period and prothrombotic defects: risk of venous thrombosis in the MEGA study. *J ThrombHaemost* 2008; 6: 632–637.
13. James AH, Jamison MG, Biswas MS, et al. Acute myocardial infarction in pregnancy: a United States population-based study. *Circulation* 2006; 113: 1564–1571.
14. Pabinger I, Grafenhofer H, Kaider A, et al. Risk of pregnancy-associated recurrent venous thromboembolism in women with a history of venous thrombosis. *Journal of Thrombosis and Haemostasis* 2005; 3: 949–954.
15. De Stefano V, Martinelli I, Rossi E, et al. The risk of recurrent venous thromboembolism in pregnancy and puerperium without antithrombotic prophylaxis. *Br J Haematol* 2006; 135: 386–391.
16. Brill-Edwards P, Ginsberg JS, Gent M, et al.; Recurrence of Clot in This Pregnancy Study Group. Safety of withholding heparin in pregnant women with a history of venous thromboembolism. *N Engl J Med* 2000; 343: 1439–1444.
17. Bezemer ID, van der Meer FJ, Eikenboom JC, et al. The value of family history as a risk indicator for venous thrombosis. *Arch Intern Med* 2009; 169: 610–615.
18. Bates SM, Greer IA, Middeldorp S, et al. VTE, thrombophilia, antithrombotic therapy, and pregnancy. *Antithrombotic Therapy and Prevention of Thrombosis, 9th ed: American College of Chest Physicians Evidence-Based Clinical Practice Guidelines*. *Chest* 2012; 141 (2 Suppl): e691S–e736S.
19. Robertson L, Wu O, Langhorne P, et al. Thrombosis: Risk and Economic Assessment of Thrombophilia Screening (TREATS)

- Study. Thrombophilia in pregnancy: a systematic review. *Br J Haematol* 2005; 132: 171 – 196.
20. Gerhardt A, Scharf RE, Zotz RB. Hereditary risk factors of thrombophilia and the individual probability of first venous thromboembolism (VTE) in pregnancy and puerperium. *J Thromb Haemost* 2015; ABS1219
 21. Rogenhofer N, Bohlmann MK, Beuter-Winkler P, et al. Prevention, management and extent of adverse pregnancy outcomes in women with hereditary antithrombin deficiency. *Ann Hematol* 2014; 93:385 – 392.
 22. Gerhardt A, Scharf RE, Beckmann MW, Struve S, et al. Prothrombin and factor V mutations in women with a history of thrombosis during pregnancy and the puerperium. *N Engl J Med* 2000; 342: 374 – 380.
 23. Liu S, Rouleau J, Joseph KS, Sauve R, et al. Epidemiology of pregnancy-associated venous thromboembolism: a population-based study in Canada. *J Obstet Gynaecol Can* 2009; 31: 611 – 620.
 24. Stone S, Hunt BJ, Khamashta MA, et al. Primary antiphospholipid syndrome in pregnancy: an analysis of outcome in a cohort of 33 women treated with a rigorous protocol. *J Thromb Haemost* 2005; 3: 243 – 5.
 25. Jacobsen AF, Skjeldestad FE, Sandset PM. Ante- and postnatal risk factors of venous thrombosis: a hospital-based case-control study. *J Thromb Haemost* 2008; 6: 905 – 912.
 26. McLintock C. Thromboembolism in pregnancy: challenges and controversies in the prevention of pregnancy-associated venous thromboembolism and management of anticoagulation in women with mechanical prosthetic heart valves. *Best Pract Res Clin Obstet Gynaecol* 2014; 28: 519 – 536.
 27. Nelson-Piercy C, MacCallum P, Mackillop L. Reducing the risk of thrombosis and embolism during pregnancy and the puerperium (Green-top guideline no. 37a). *Royal College of Obstetricians and Gynaecologists* 2015; 1 – 40.
 28. Virkus RA, Løkkegaard E, Lidegaard Ø et al. Risk factors for venous thromboembolism in 1.3 million pregnancies: a nationwide prospective cohort. *PLoS One* 2014; 9: e96495.
 29. Chan WS, Dixon ME. The “ART” of thromboembolism: a review of assisted reproductive technology and thromboembolic complications. *Thromb Res* 2008; 121: 713 – 726.
 30. Rova K, Passmark H, Lindqvist PG. Venous thromboembolism in relation to in vitro fertilization: an approach to determining the incidence and increase in risk in successful cycles. *FertilSteril* 2012; 97: 95 – 100.
 31. Henriksson P, Westerlund E, Wallen H, et al. Incidence of pulmonary and venous thromboembolism in pregnancies after in vitro fertilisation: cross sectional study. *BMJ* 2013; 346: e8632.
 32. Hansen AT, Kesmodel US, Juul S, et al. Increased venous thrombosis incidence in pregnancies after in vitro fertilization. *Hum Reprod* 2014; 29: 611 – 617.
 33. Bauersachs RM, Manolopoulos K, Hoppe I, et al. More on: the „ART“ behind the clot: solving the mystery. *J Thromb Haemost* 2007; 5: 438 – 439.
 34. Arya R, Shehata HA, Patel RK, et al. Internal jugular vein thrombosis after assisted conception therapy. *Br J Haematol* 2001; 115: 153 – 155.
 35. Nelson SM. Prophylaxis of VTE in women – during assisted reproductive techniques. *Thromb Res* 2009; 123 Suppl 3: S8 – S15.
 36. Jacobsen AF, Sandset PM. Venous thromboembolism associated with pregnancy and hormonal therapy. *Best Pract Res Clin Haematology* 2012; 25: 319 – 332.
 37. Bergrem A, Astrup Dahm AE, Jacobsen AF, et al. Resistance to activated protein C is a risk factor for pregnancy-related venous thrombosis in the absence of the F5 rs6025 (factor V Leiden) polymorphism. *Br J Haematol* 2011; 154: 241 – 247.
 38. Szecsi PB, Jørgensen M, Klajnbard A, et al. Haemostatic reference intervals in pregnancy. *Thromb Haemost* 2010; 103: 718 – 727.
 39. Bates SM, Ginsberg JS. Thrombosis in pregnancy. *Curr Opin Hematol* 1997; 4: 335 – 343.
 40. Ikard RW, Ueland K, Folse R. Lower limb venous dynamics in pregnant women. *Surgery Gynecology and Obstetrics with International Abstracts of Surgery* 1971; 132: 483.
 41. Greer IA. Thrombosis in pregnancy: maternal and fetal issues. *Lancet* 1999; 353: 1258 – 1265.
 42. Chan WS, Spencer FA, Ginsberg JS. Anatomic distribution of deep vein thrombosis in pregnancy. *CMAJ* 2010; 182: 657 – 60.
 43. May R, Thurner J. The cause of the predominantly sinistral occurrence of thrombosis of the pelvic veins. *Angiology* 1957; 8: 419 – 427.
 44. Cockett FB, Thomas ML, Negus D. Iliac vein compression - Its relation to iliofemoral thrombosis and post-thrombotic syndrome. *Br Med J* 1967; 2: 214 – 219.
 45. Chan WS, Lee A, Spencer FA, et al. Predicting deep venous thrombosis in pregnancy: out in „LEFT“ field? *Ann Intern Med* 2009; 151: 85 – 92.
 46. Righini M, Jobic C, Boehlen F, et al., and the EDVIGE study group. Predicting deep venous thrombosis in pregnancy: external validation of the LEFT clinical prediction rule. *Haematologica* 2013; 98: 545 – 548.
 47. Regitz-Zagrosek V, Blomstrom LC, Borghi C, et al. ESC Guidelines on the management of cardiovascular diseases during pregnancy: the Task Force on the Management of Cardiovascular Diseases during Pregnancy of the European Society of Cardiology (ESC). *Eur Heart J* 2011; 32: 3147 – 3197.
 48. Blanco-Molina A, Rota L, Di Micco P, et al., for the RIETE Investigators. Venous thromboembolism during pregnancy, postpartum or during contraceptive use. Findings from the RIETE Registry. *Thromb Haemost* 2010; 103: 306 – 311.
 49. Leung AN, Bull TM, Jaeschke R, et al., on behalf of the ATS/STR Committee on Pulmonary Embolism in Pregnancy. An Official American Thoracic Society/Society of Thoracic Radiology Clinical Practice Guideline: Evaluation of suspected pulmonary embolism in pregnancy. *Radiology* 2012; 262: 635 – 646.
 50. Bates SM, Jaeschke R, Stevens SM, et al. Diagnosis of DVT. Antithrombotic Therapy and Prevention of Thrombosis, 9th ed: American College of Chest Physicians Evidence-Based Clinical Practice Guidelines. *Chest* 2012; 141(2)(Suppl): e351S – e418S.
 51. Hach-Wunderle V, Gerlach H, Konstantinides S, et al. Interdisziplinäre S2k-Leitlinie: Diagnostik und Therapie der Bein- und Beckenvenenthrombose und der Lungenembolie: Registernummer 065 – 002. *VASA* 2016; 45 (Suppl 91): in press
 52. Johnson SA, Stevens SM, Woller SC, et al. Risk of deep vein thrombosis following a single negative whole-leg compression ultrasound: a systemic review and meta-analysis. *JAMA* 2010; 303: 438 – 445.
 53. Elias A, Mallard L, Elias M, et al. A single complete ultrasound investigation of the venous network for the diagnostic management of patients with a clinically suspected first episode of deep venous thrombosis of the lower limbs. *Thromb Haemost* 2003; 89: 221 – 227.
 54. Schellong SM, Schwarz T, Halbritter K et al. Complete compression ultrasonography of the leg veins as a single test for the diagnosis of deep vein thrombosis. *Thromb Haemost* 2003; 89: 228 – 234.
 55. Sevestre MA, Labarere J, Casez P, et al. Accuracy of complete compression ultrasound in ruling out suspected deep venous thrombosis in the ambulatory setting. A prospective cohort study. *Thromb Haemost* 2009; 102: 166 – 172.
 56. Stevens SM, Elliott CG, Chan KJ, et al. Withholding anticoagulation after a negative result on duplex ultrasonography for suspected symptomatic deep venous thrombosis. *Ann Intern Med* 2004; 140: 985 – 991.
 57. Subramaniam RM, Heath R, Chou T, et al. Deep venous thrombosis: withholding anticoagulation therapy after negative complete lower limb US findings. *Radiology* 2005; 237: 348 – 352.
 58. Le Gal G, Kerret G, Yhmed KB, et al., on behalf of the EDVIGE study group. Diagnostic value of single complete compression ultrasonography in pregnant and postpartum women

- with suspected deep vein thrombosis: prospective study. *BMJ* 2012; 344: e2635.
59. Le Gal G, Prins AM, Righini M, et al. Diagnostic value of a negative single complete compression ultrasound of the lower limbs to exclude the diagnosis of deep venous thrombosis in pregnant or postpartum women: a retrospective hospital-based study. *Thromb Res* 2006; 118: 691–697.
 60. Chan WS, Pencer FA, Lee AY, et al. Safety of withholding anticoagulation in pregnant women with suspected deep vein thrombosis following negative serial compression ultrasound and iliac vein imaging. *CMAJ* 2013; 185: E194–E200.
 61. Chan WS, Chunilal S, Lee A, et al. A red blood cell agglutination D-dimer test to exclude deep venous thrombosis in pregnancy. *Ann Intern Med* 2007; 147: 165–170.
 62. De Wilde JP, Rivers AW, Price DL. A review of the current use of magnetic resonance imaging in pregnancy and safety implications for the fetus. *Prog Biophys Mol Biol* 2005; 87: 335–353.
 63. Wang PI, Chong ST, Kielar AZ, et al. Imaging of pregnant and lactating patients: part I, evidence-based review and recommendations. *AJR Am J Roentgenol* 2012; 198: 778–784.
 64. Kanal E, Barkovich AJ, Bell C, et al. ACR guidance document for safe MR practices: 2007. *AJR Am J Roentgenol* 2007; 188: 1447–1474.
 65. Lin SP, Brown JJ. MR agents: physical and pharmacologic basics. *J Magn Reson Imaging* 2007; 25: 884–899.
 66. Webb JA, Thomsen HS, Morcos SK. The use of iodinated and gadolinium contrast media during pregnancy and lactation. *Eur Radiol* 2005; 15: 1234–1240.
 67. Catalano C, Pavone P, Laghi A, et al. Role of MR venography in the evaluation of deep venous thrombosis. *Acta Radiol* 1997; 38: 907–912.
 68. Torkzad MR, Bremme K, Hellgren M, et al. Magnetic resonance imaging and ultrasonography in diagnosis of pelvic vein thrombosis during pregnancy. *Thromb Res* 2010; 126: 107–112.
 69. Masselli G, Brunelli R, Casciani E, et al. Acute abdominal and pelvic pain in pregnancy: MR imaging as a valuable adjunct to ultrasound? *Abdom Imaging* 2011; 36: 596–603.
 70. Clements H, Duncan KR, Fielding K, et al. Infants exposed to MRI in utero have a normal paediatric assessment at 9 months. *Br J Radiol* 2000; 73: 190–194.
 71. Kok RD, de Vries MM, Heerschap A, et al. Absence of harmful effects of magnetic resonance exposure at 1.5 T in utero during the third trimester of pregnancy: a follow-up study. *Magn Reson Imaging* 2004; 22: 851–854.
 72. Ginsberg JS, Hirsh J, Rainbow AJ, et al. Risks to the fetus of radiologic procedures used in the diagnosis of maternal venous thromboembolic disease. *Thromb Haemost* 1989; 61: 189–196.
 73. Thomas SM, Goodacre SW, Sampson FC, et al. Diagnostic value of CT for deep vein thrombosis: results of a systematic review and meta-analysis. *Clin Radiol* 2008; 63: 299–304.
 74. Konstantinides SV, Torbicki A, Agnelli G, et al.; Task Force for the Diagnosis and Management of Acute Pulmonary Embolism of the European Society of Cardiology (ESC). 2014 ESC guidelines on the diagnosis and management of acute pulmonary embolism. *Eur Heart J* 2014; 35: 3033–3080.
 75. Patel C, Scarsbrook A, Gleeson F. Pulmonary embolism in pregnancy. *Lancet* 2010; 375: 1778.
 76. Bourjeily G, Khalil H, Rodger M. Pulmonary embolism in pregnancy. Author's reply. *Lancet* 2010; 375: 1778–1779.
 77. Daftary A, Gregory M, Daftary A, et al. Chest radiograph as a triage tool in the imaging-based diagnosis of pulmonary embolism. *AJR Am J Roentgenol* 2005; 185: 132–134.
 78. Chan WS, Ray JG, Murray S, et al. Suspected pulmonary embolism in pregnancy: clinical presentation, results of lung scanning, and subsequent maternal and pediatric outcomes. *Arch Intern Med* 2002; 162: 1170–1175.
 79. Bourjeily G, Khalil H, Raker C, et al. Outcomes of negative multi-detector computed tomography with pulmonary angiography in pregnant women suspected of pulmonary embolism. *Lung* 2012; 190: 105–111.
 80. Ridge CA, McDermott S, Freyne BJ, et al. Pulmonary embolism in pregnancy: comparison of pulmonary CT angiography and lung scintigraphy. *AJR Am J Roentgenol* 2009; 193: 1223–1227.
 81. U-King-Im JM, Freeman SJ, Boylan T, et al. Quality of CT pulmonary angiography for suspected pulmonary embolus in pregnancy. *Eur Radiol* 2008; 18: 2709–2715.
 82. Scarsbrook AF, Bradley KM, Gleeson FV. Perfusion scintigraphy: diagnostic utility in pregnant women with suspected pulmonary embolic disease. *Eur Radiol* 2007; 17: 2554–2560.
 83. Ridge CA, Mhuicheartaigh JN, Dodd JD et al. Pulmonary CT angiography protocol adapted to the hemodynamic effects of pregnancy. *AJR Am J Roentgenol* 2011; 197: 1058–1063.
 84. Revel MP, Cohen S, Sanchez O, et al. Pulmonary embolism during pregnancy: diagnosis with lung scintigraphy or CT angiography? *Radiology* 2011; 258: 590–598.
 85. Shahir K, Goodman LR, Tali A, et al. Pulmonary embolism in pregnancy: CT pulmonary angiography versus perfusion scanning. *AJR Am J Roentgenol* 2010; 195: W214–W220.
 86. Cahill AG, Stout MJ, Macones GA, et al. Diagnosing pulmonary embolism in pregnancy using computed-tomographic angiography or ventilation-perfusion. *Obstet Gynecol* 2009; 114: 124–129.
 87. Niemann T, Nicolas G, Roser HW, et al. Imaging for suspected pulmonary embolism in pregnancy – what about the fetal dose? A comprehensive review of the literature. *Insights Imaging* 2010; 1: 361–372.
 88. International Commission on Radiological Protection. Pregnancy and medical radiation. ICRP Publication 84. *Ann ICRP* 2000; 30(1): 1–43.
 89. Tremblay E, Therasse E, Thomassin-Naggara I, et al. Guidelines for use of medical imaging during pregnancy and lactation. *Radiographics* 2012; 32: 897–911.
 90. Boone JM, Cooper VN III, Nemzek WR, et al. Monte Carlo assessment of computed tomography dose to tissue adjacent to the scanned volume. *Med Phys* 2000; 27: 2393–2407.
 91. Ray JG, Schull MJ, Urquia ML, et al. Major radiodiagnostic imaging in pregnancy and the risk of childhood malignancy: a population-based cohort study in Ontario. *PLoS Med* 2010; 7: e1000337.
 92. Chen J, Lee RJ, Tsodikov A, et al. Does radiotherapy around the time of pregnancy for Hodgkin's disease modify the risk of breast cancer? *Int J Radiat Oncol Biol Phys* 2004; 58: 1474–1479.
 93. Ronckers CM, Erdmann CA, Land CE. Radiation and breast cancer: a review of current evidence. *Breast Cancer Res* 2005; 7: 21–32.
 94. Scarsbrook AF, Evans AL, Owen AR, et al. Diagnosis of suspected venous thromboembolic disease in pregnancy. *Clin Radiol* 2006; 61: 1–12.
 95. Hurwitz LM, Reiman RE, Yoshizumi TT, et al. Radiation dose from contemporary cardiothoracic multidetector CT protocols with an anthropomorphic female phantom: implications for cancer induction. *Radiology* 2007; 245: 742–750.
 96. Bourjeily G, Chalhoub M, Phornphutkul C, et al. Neonatal thyroid function: effect of a single exposure to iodinated contrast medium in utero. *Radiology* 2010; 256: 744–750.
 97. Rajaram S, Exley CE, Fairlie F, et al. Effect of antenatal iodinated contrast agent on neonatal thyroid function. *Br J Radiol* 2012; 85: 238–242.
 98. Webb JA. Pregnancy and lactation: intravascular use of contrast media. In: Thomsen H, Webb JA (Hrsg.). *Contrast media: safety issues and ESUR guidelines*, 3rd edition, Berlin-Heidelberg, 2014.
 99. Ito S. Drug therapy for breast-feeding women. *N Engl J Med* 2000; 343: 118–126.
 100. Kluge A, Luboldt W, Bachmann G. Acute pulmonary embolism to the subsegmental level: diagnostic accuracy of three MRI techniques compared with 16-MDCT. *AJR Am J Roentgenol* 2006; 187: W7–14.

101. Heredia V, Altun E, Ramalho M, et al. MRI of pregnant patients for suspected pulmonary embolism: steady-state free precession vs. postgadolinium 3D-GRE. *Acta Med Port* 2012; 25: 359–367.
102. Nijkeuter M, Geleijns J, de Roos A, et al. Diagnosing pulmonary embolism in pregnancy: rationalizing fetal radiation exposure in radiological procedures. *J ThrombHaemost* 2004; 2: 1857–1858.
103. Kline JA, Richardson DM, Than MP, et al. Systematic review and meta-analysis of pregnant patients investigated for suspected pulmonary embolism in the emergency department. *Acad Emerg Med* 2014; 21: 949–959.
104. Wells PS, Anderson DR, Bormanis J, et al. Value of assessment of pretest probability of deep-vein thrombosis in clinical management. *Lancet* 1997; 350: 1795–1798.
105. Wicki J, Perneger TV, Junod AF, et al. Assessing clinical probability of pulmonary embolism in the emergency ward: a simple score. *Arch Intern Med* 2001; 161: 92–97.
106. Le Gal G, Righini M, Roy PM, et al. Prediction of pulmonary embolism in the emergency department: the revised Geneva score. *Ann Intern Med* 2006; 144: 165–171.
107. O'Connor C, Moriarty J, Walsh J, et al. The application of a clinical risk stratification score may reduce unnecessary investigations for pulmonary embolism in pregnancy. *J Matern Fetal Neonatal Med* 2011; 24: 1461–1464.
108. Cutts BA, Tran HA, Merriman E, et al. The utility of the Wells clinical prediction model and ventilation-perfusion scanning for pulmonary embolism diagnosis in pregnancy. *Blood Coagul Fibrinolysis* 2014; 25: 375–378.
109. Dargaud Y, Hierso S, Rugeri L, et al. Endogenous thrombin potential, prothrombin fragment 1+2 and D-dimers during pregnancy. *Thromb Haemost.* 2010; 103: 469–471.
110. Kline JA, Williams GW, Hernandez-Nino J. D-dimer concentrations in normal pregnancy: new diagnostic thresholds are needed. *Clin Chem* 2005; 51: 825–829.
111. Morse M. Establishing a normal range for D-dimer levels through pregnancy to aid in the diagnosis of pulmonary embolism and deep vein thrombosis. *J Thromb Haemost.* 2004; 2: 1202–1204.
112. Yamada T, Kawaguchi S, Araki N, et al. Difference in the D-dimer rise between women with singleton and multifetal pregnancies. *Thromb Res* 2013; 131: 493–496.
113. Nishii A, Noda Y, Nemoto R, et al. Evaluation of D-dimer during pregnancy. *J Obstet Gynaecol Res* 2009; 35: 689–693.
114. Nolan TE, Smith RP, Devoe LD. Maternal plasma D-dimer levels in normal and complicated pregnancies. *ObstetGynecol* 1993; 81: 235–238.
115. Nelson SM. Venous thrombosis during assisted reproduction: novel risk reduction strategies. *Thromb Res* 2013; 131 Suppl 1: S1–S3.
116. Kjellberg U, van Rooijen M, Bremme K, et al. Increased activation of blood coagulation in pregnant women with the Factor V Leiden mutation. *Thromb Res* 2014; 134: 837–845.
117. Patel JP, Patel RK, Roberts LN, et al. Changes in thrombin generation and D-dimer concentrations in women injecting enoxaparin during pregnancy and the puerperium. *BMC Pregnancy and Childbirth* 2014; 14: 384.
118. Kovac M, Mikovic Z, Rakicevic L, et al. The use of D-dimer with new cutoff can be useful in diagnosis of venous thromboembolism in pregnancy. *Eur J Obstet Gynecol* 2010; 148: 27–30.
119. Wang M, Lu S, Li S, et al. Reference intervals of D-dimer during the pregnancy and puerperium period on the STA-R evolution coagulation analyzer. *ClinChimActa* 2013; 425: 176–180.
120. Chan WS, Lee A, Spencer FA, et al. D-dimer testing in pregnant patients: towards determining the next “level” in the diagnosis of DVT. *J Thromb Haemost* 2010; 8: 1004–1011.
121. Murphy N, Broadhurst DI, Khashan AS, et al. Gestation-specific D-dimer reference ranges: a cross-sectional study. *BJOG* 2015; 122: 395–400.
122. DeStefano V, Leone G, Mastrangelo S, et al. Thrombosis During Pregnancy and Surgery in Patients with Congenital Deficiency of Antithrombin-III, Protein-C, Protein-S. *Thrombosis and Haemostasis* 1994; 71: 799–800.
123. Conard J, Horellou MH, Vandredon P, et al. Thrombosis and Pregnancy in Congenital Deficiencies in At-III, Protein-C Or Protein-S - Study of 78 Women. *Thrombosis and Haemostasis* 1990; 63: 319–320.
124. Bucciarelli P, Passamonti SM, Biguzzi E, et al. Low borderline plasma levels of antithrombin, protein C and protein S are risk factors for venous thromboembolism. *J Thromb Haemost* 2012; 10: 1783–1791.

Submitted: 20.11.2015

Accepted: 21.11.2015

There are no conflicts of interest existing.

Correspondence address

Priv.-Doz. Dr. Birgit Linnemann
 Medical Practice of Angiology and Haemostaseology
 Praxis am Grüneburgweg
 Grüneburgweg 12
 60322 Frankfurt/Main
 Germany

linnemann@praxis-am-grueneburgweg.de